

Surgical Extractions

Dr Ven Woo
Dr Ken Lin

Disclaimer

- This talk is aimed to give a practical approach to cases seen in the Oral & Maxillofacial Surgery extraction clinics and potentially in future practice for graduating dentists.
- As accurate as possible (backed by literature) but please do not only rely on this lecture for your exams.
- Contents of the lecture are based on our clinical experience and what we were taught. There may be some discrepancies among preferences and approaches to treatment compared to other clinicians. There are multiple ways to do things.
- The authors of this talk do not accept any responsibility or liability relating to the use of this information.

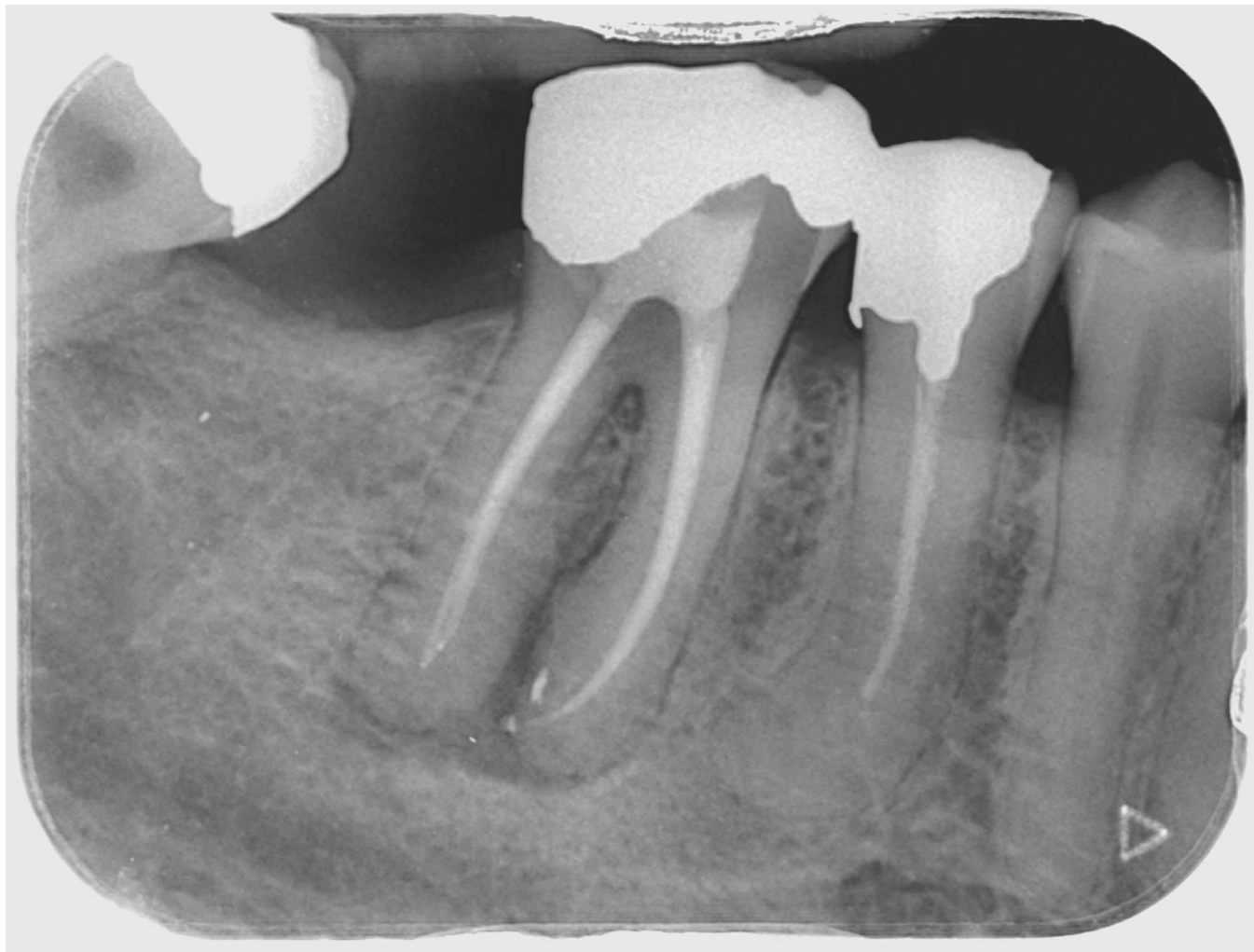Lecture Overview

Surgical extractions

Third molar extractions

Case discussions

Surgical Extractions



When to consider surgical extractions?

History of difficult extractions

History of failed extractions

Remaining tooth structure - including location of caries, previous RCT

Complex roots

Bulbous roots

Hypercementosis

Ankylosis

Dense alveolar bone

Impaction

Principles of surgical extractions

Anatomy - neurovascular structures

Soft tissue flap design

- Access is key!

Use of correct burs and instruments

Recognise the indications for surgical extractions

Management of outcomes of surgical extractions

- Soft tissue re-approximation

Additional armamentarium

Scalpel

Periosteal elevator (Molt)

Mitchell's trimmer

Curved artery forceps

Retractors - Minnesota, bone hook

Surgical handpiece and bur with irrigation with sterile saline

Bite block

Suturing instruments - needle holder, Gilles forceps, suture scissors, wire check retractor

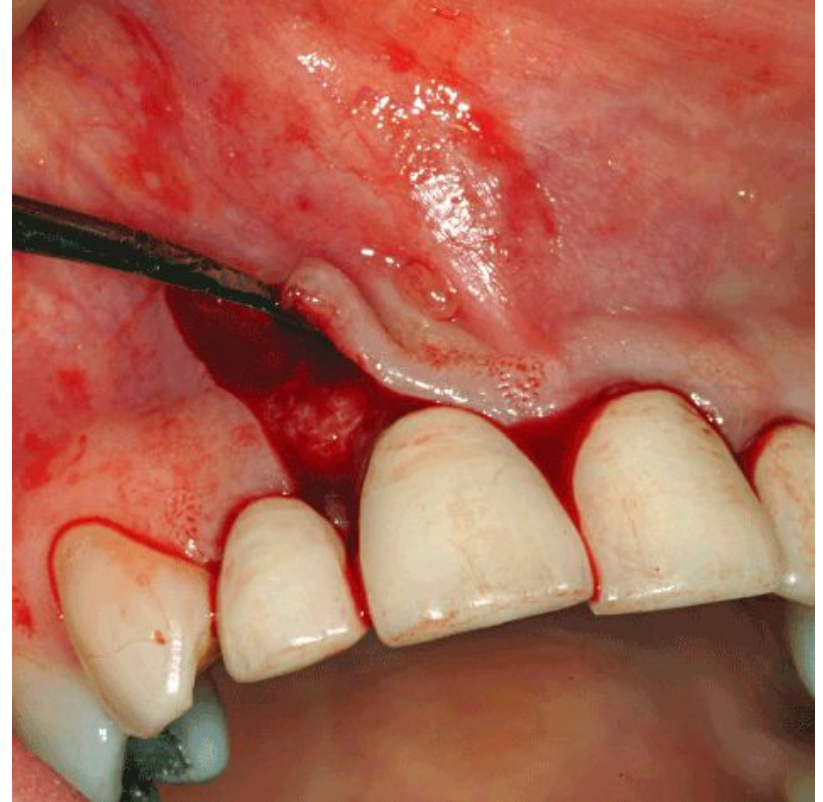
Steps for surgical extraction

1. Mucoperiosteal flap - consideration of flap design
2. Removal of bone
3. Section +/- decoronation
4. Create point of elevation
5. Elevation of roots
6. Wound toilet
7. Haemostasis - consideration of haemostatic agents, sutures

Flap design: General principles

Principles:

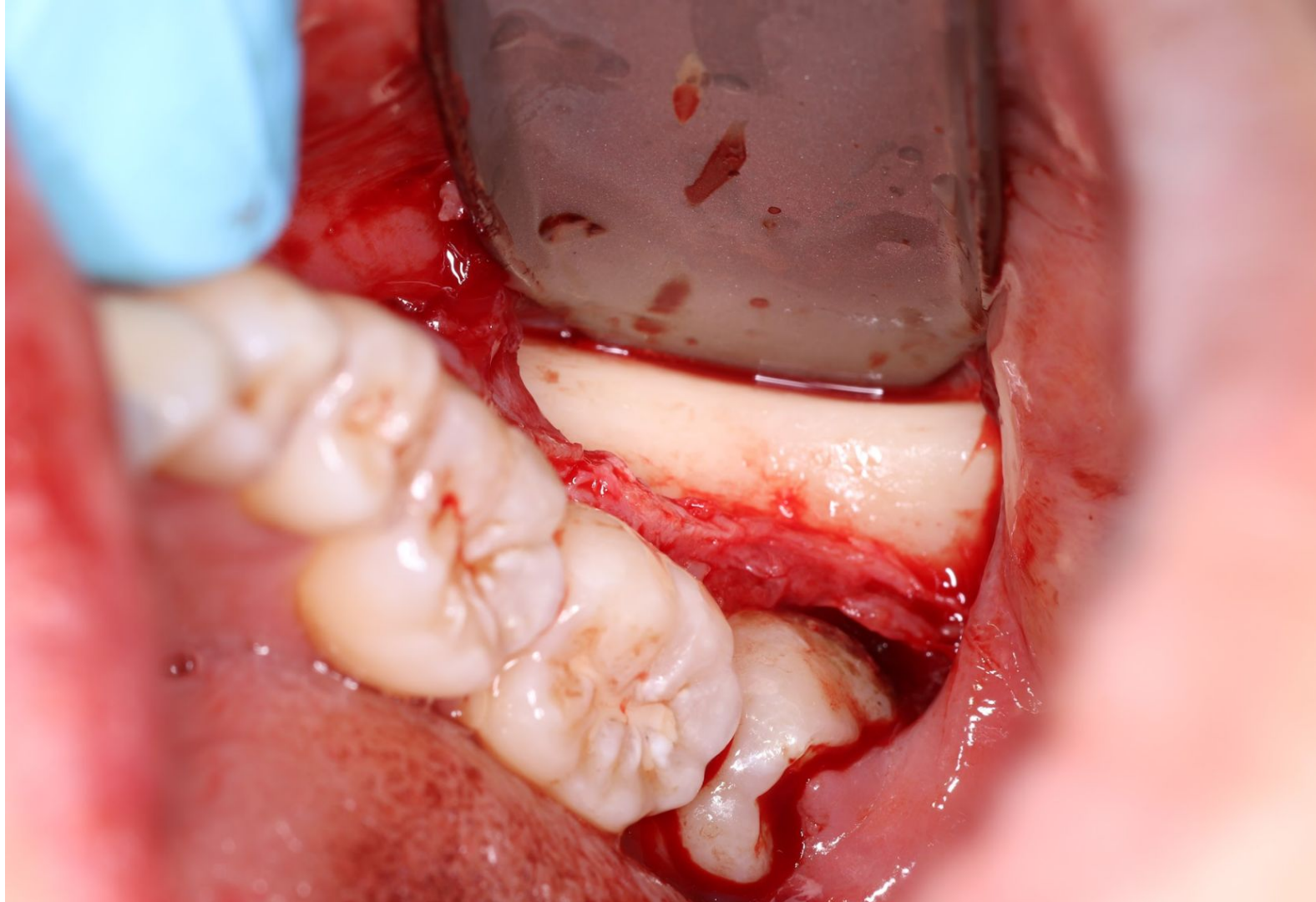
1. Base of flap should be broader than the free end to maintain tissue vascularity
Width of flap is twice as long as its height
2. Incision should be placed over sound bone and at right angle
3. Vertical relieving incision should start from the buccal vestibule and end mesial or distal to the interdental papilla
Made at an obtuse angle



Flap design: General principles

Tips:

- Ensure flap is large enough for adequate visualisation of the surgical field
- Avoid incising near neurovascular structures - **know your anatomy**
- Avoid incising through gingival papilla
- Avoid incisions that transect the crestal gingiva on the buccal convexities of the teeth
- Sharp, clean, precise incisions straight down to bone
- Full thickness elevation of tissues (mucosa, submucosa, muscle, periosteum) in a single layer
- Avoid tension on the flap (blanching)
- When resting the retractor (e.g. Minnesota), it should be resting on healthy bone and not the flap



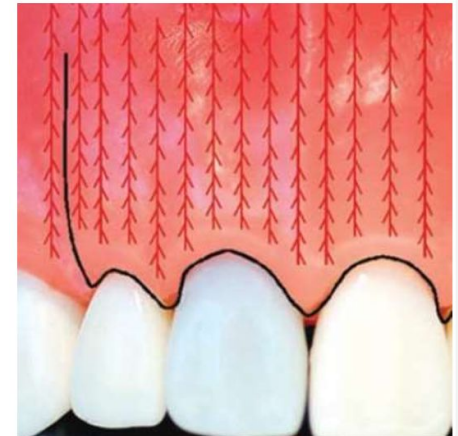
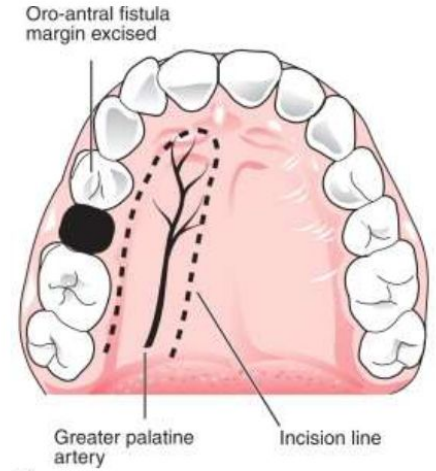
Blood supply for flap

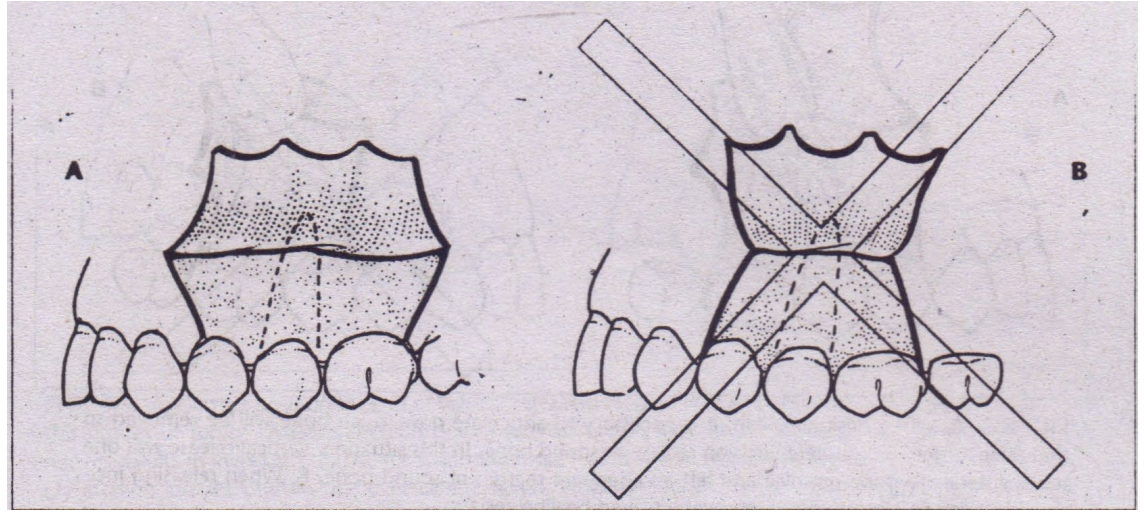
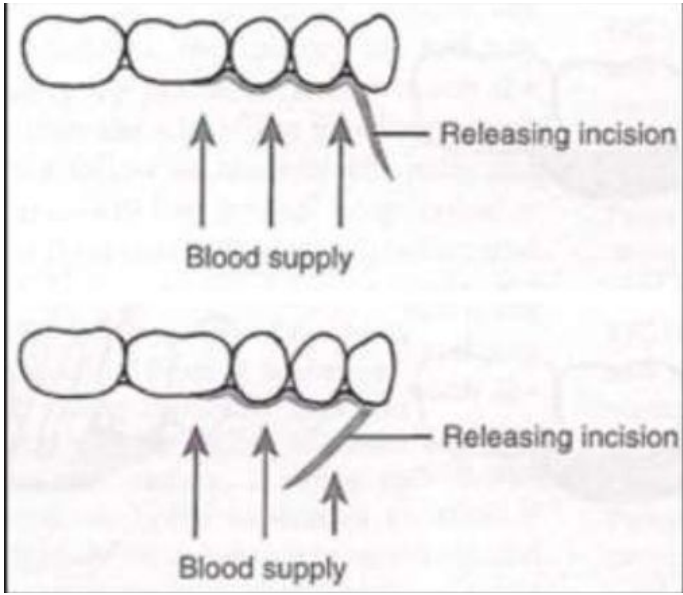
Axial blood supply

- Known artery/vein supplying length of flap
- Eg. palatal flap with greater palatine vessels

Random blood supply

- No definite artery/vein for flap
- Dependent on microvascular supply
- Eg. vascular supply to labial/buccal alveolar mucosa and gingiva runs vertically from apical to coronal direction

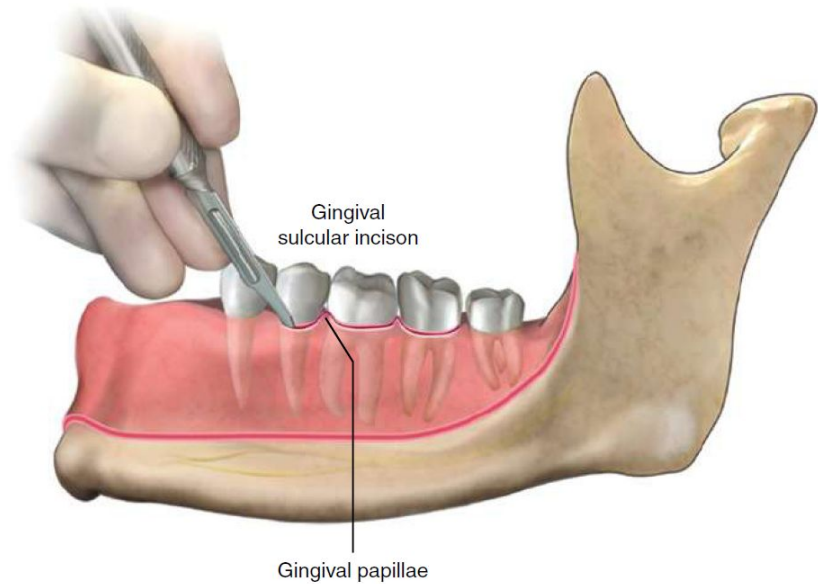




Flap design

Crestal/envelope flap

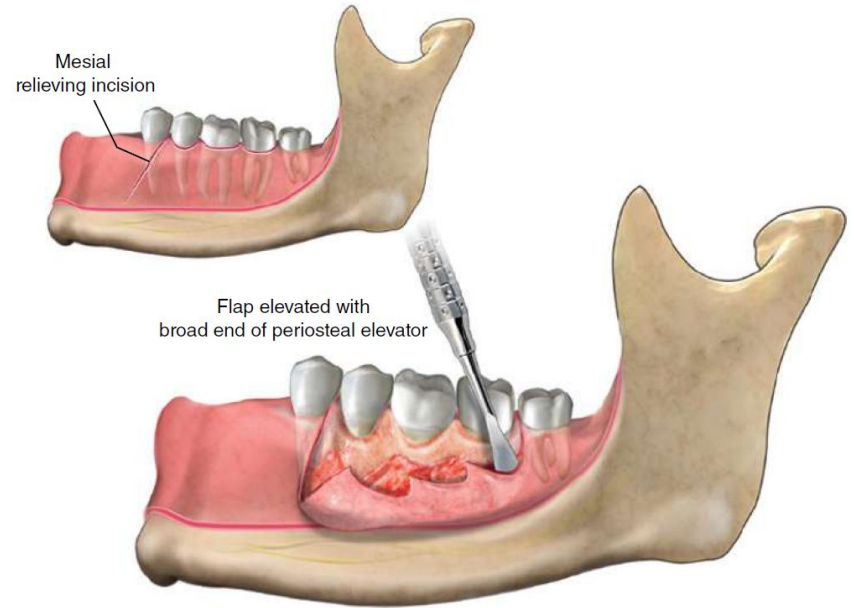
- Incision that is made in the sulcus of the gingiva surrounding teeth
- Elevation of mucoperiosteal flap from bony alveolar crest
- Access is limited to the stretch of the keratinised gingival tissue



Flap design

Two-sided flap (triangular flap)

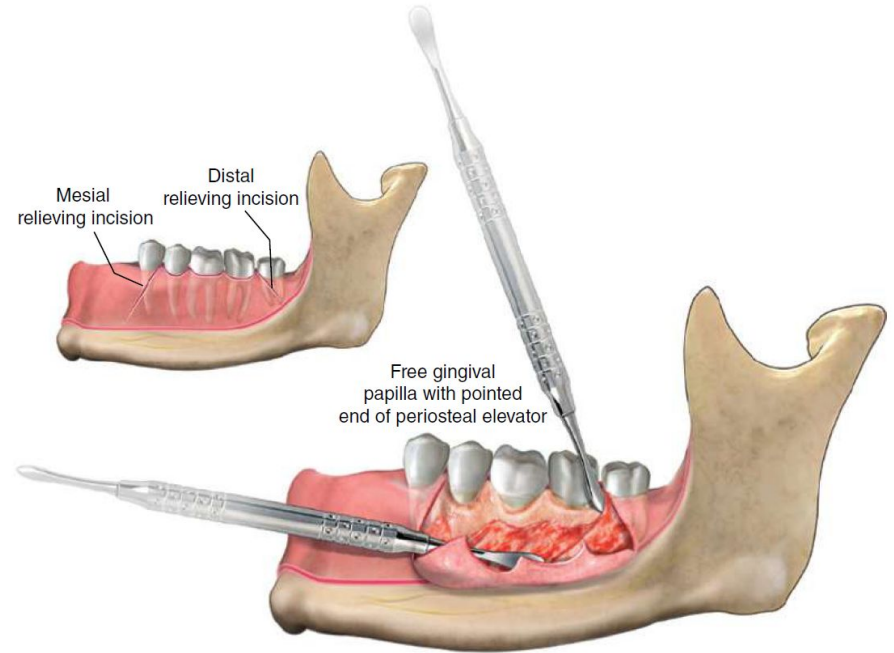
- One relieving incision (apical extension of a crestal flap) + crestal incision



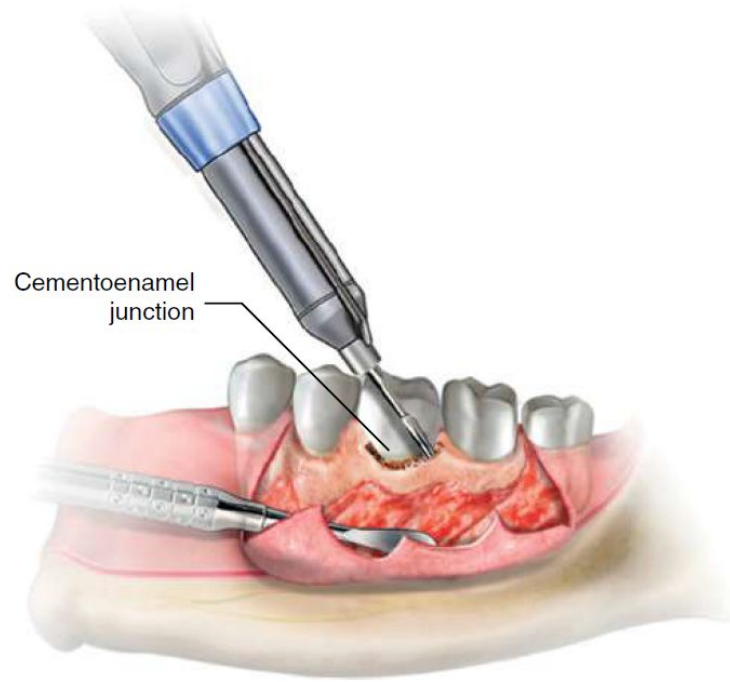
Flap design

Three-sided flap (trapezoidal flap)

- Two relieving incisions (apical extension of a crestal flap) + crestal incision

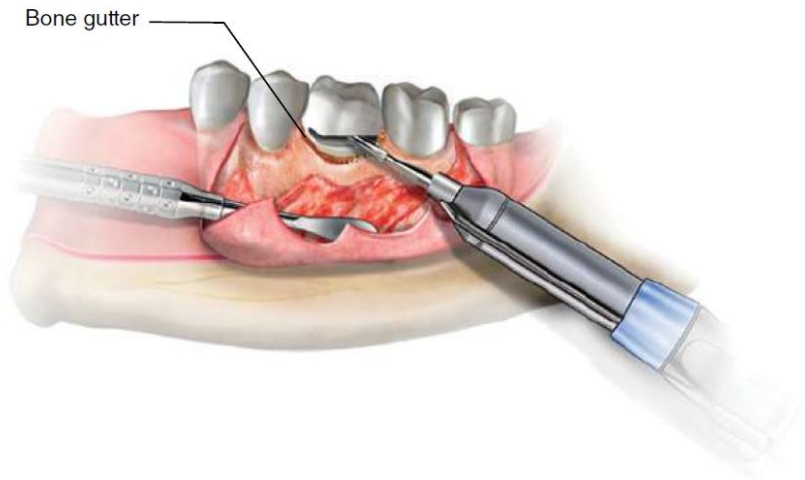


Bone removal

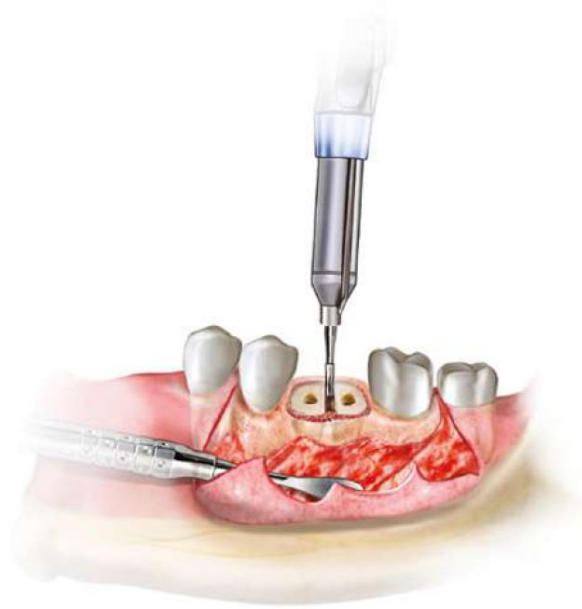


Tooth sectioning

Decoronation



Section



Assessment after extraction

Assess socket for debris, tooth fragments, iatrogenic damage

Irrigate then curettage - also consider removal of plaque/calculus of adjacent teeth

Copious irrigation of socket with saline

Examination of socket for bleeding, alveolar bone fracture, soft tissue trauma

+/- Compression of socket

Haemostasis *haemostatic agents will be discussed in 'Management of the Medically Compromised patient'

Closure

Repositioning of soft tissue flap to original position with sutures

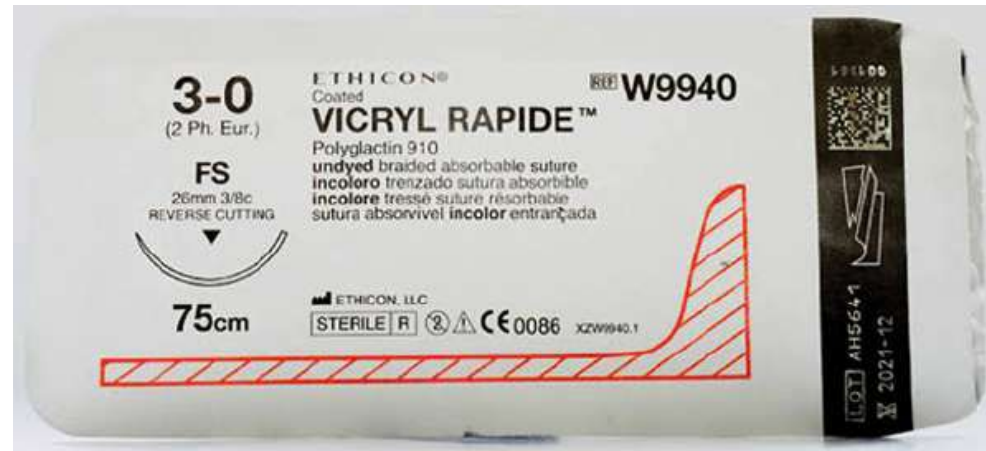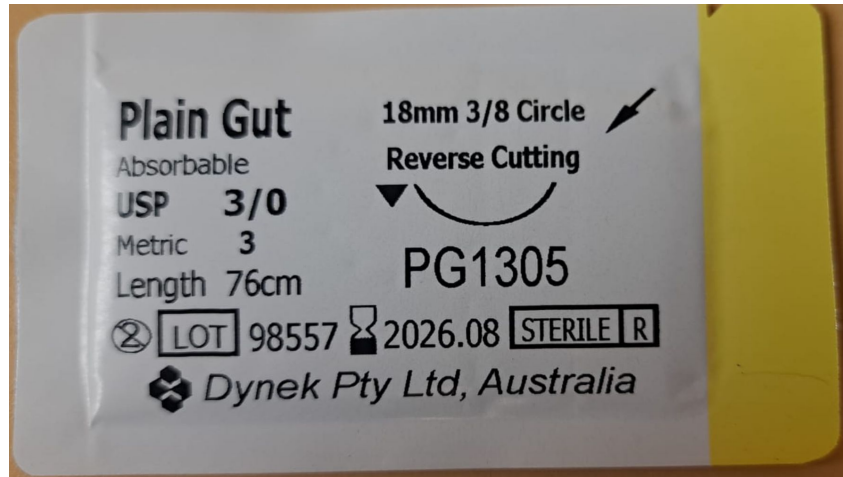
Aim is to restore the periodontal contour of the alveolus

Suture classification:

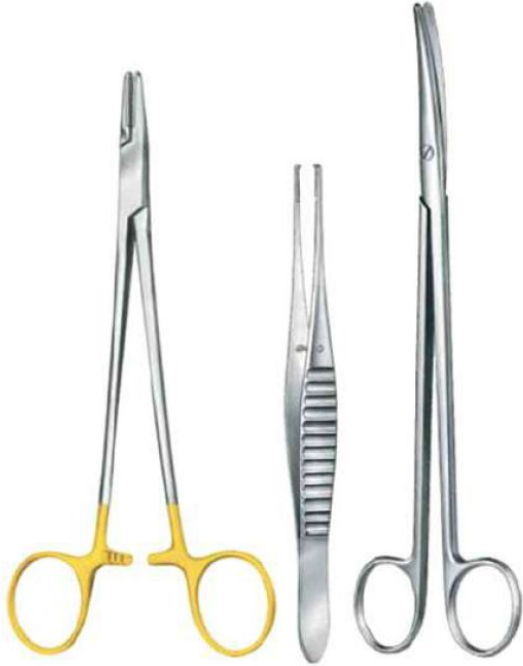- Natural vs synthetic
- Absorbable vs non-absorbable
- Monofilament vs braided
- Size

https://www.aaoms.org/docs/education_research/dental_students/joms_guide_to_suturing.pdf

Suture Materials



Sutures: Instruments



Needle holders


Gilles forceps

- Grasp periodontal tissue
- Held similar to a pen, with thumb and forefinger controlling the tips of the instrument

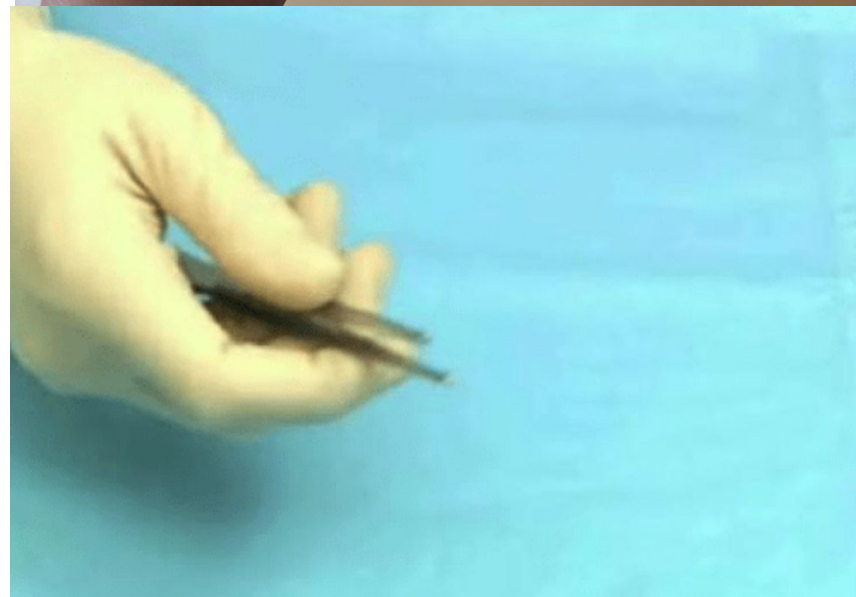
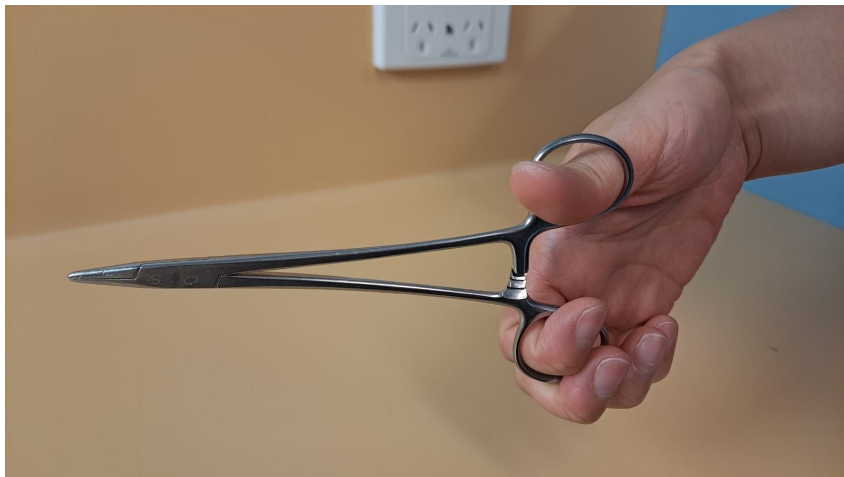
Suture scissor

Wire cheek retractor



Suturing: Handling of Instruments




Suturing: Incorrect Handling



Suturing: Handling of needle



Suturing: Incorrect handling of needle



Suturing: Technique

Interrupted - most common

Others

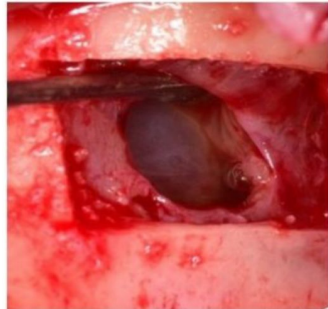- Vertical mattress
- Horizontal mattress
- Continuous locking
- Continuous non-locking
- Cruciate/figure-of-eight

Complications

Oroantral Communication

OAC: unnatural communication between the maxillary sinus and oral cavity

OAF: epithelialized pathological unnatural communication between the maxillary sinus and oral cavity. Develops when OAC fails to close spontaneously, remains patent and epithelialises. Occurs when the perforation persists for > 48 hours.



Presentation

Early

- Passage of air
- Regurgitation of liquid
- Epistaxis

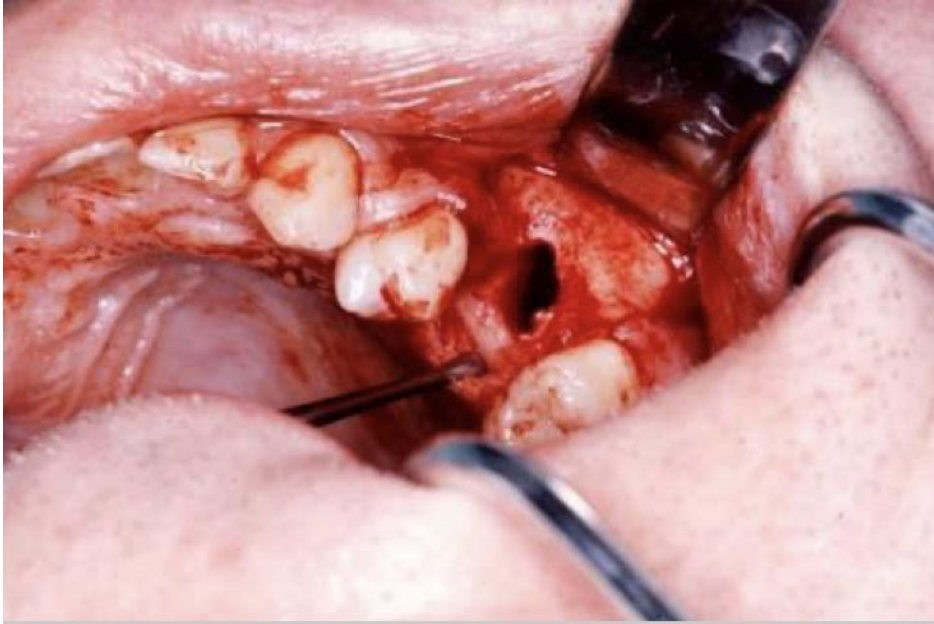
Late

- Discharge
- Sinusitis

Prevention

- Expectation vs. complication
- Assessment and extraction technique

Oroantral Communication



Inspection

- Suction the socket to visually inspect socket (*Careful not to push the suction too far and actually make an OAC when there wasn't one)
- Irrigate with saline and ask patient if they can feel water in their nose

Valsalva technique:

- Hold patient's nose and get them to blow, listen for any passage of air or bubbles (*Careful not to create an OAC if sinus lining is intact)

Oroantral Communication

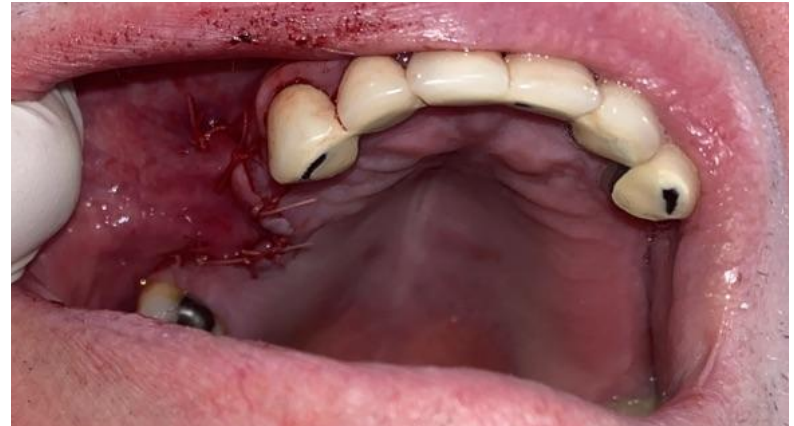Management

Small defects < 5mm spontaneously resolve; ≥ 5 mm require surgical repair

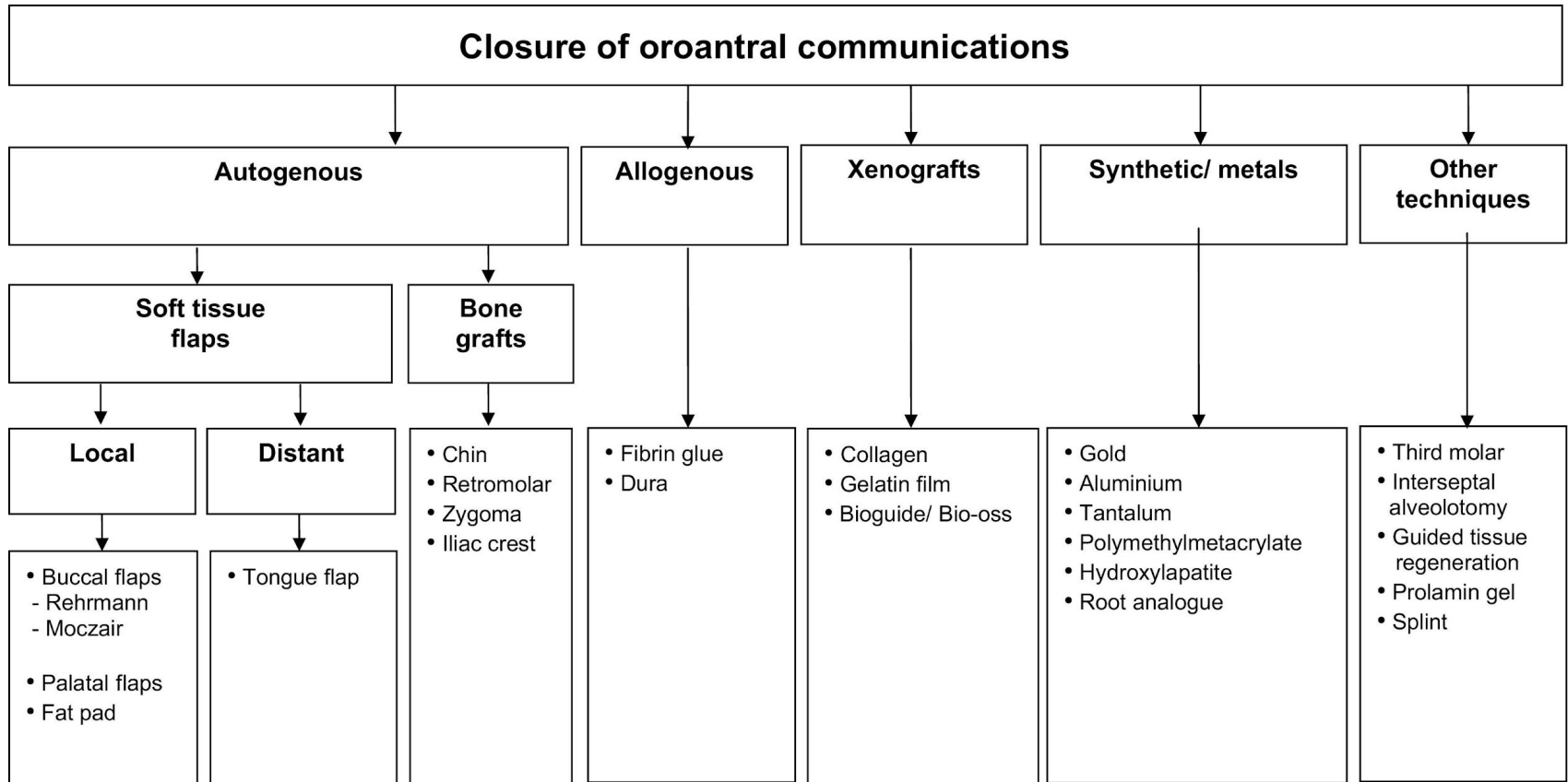
- Buccal advancement flap
- Buccal fat pad
- Rotated palatal flap
- Bone
- Oro-antral regime

Layers

- Bone - first layer
- Buccal fat pad - second layer
- Flap advancement of mucosa - third layer



Flaps - will have more resorption, minimal keratinised tissue → complications with dentures and implants



Oroantral Communication

Sinus precautions/regime

- No negative pressure: no nose blowing for 2/52, no smoking, no wind instruments, no drinking through a straw
- Sneeze with an open mouth
- Broad spectrum Abx
 - Amoxicillin/clavulanic acid 875mg/125mg
- Nasal decongestant
 - Only use for < 5 days or else will get nasal decongestion rebound
- Analgesia
- Avoid swimming 4/12, avoid strenuous exercise 1/52
- Bleeding through the nose is not uncommon
- Review 2-4/52

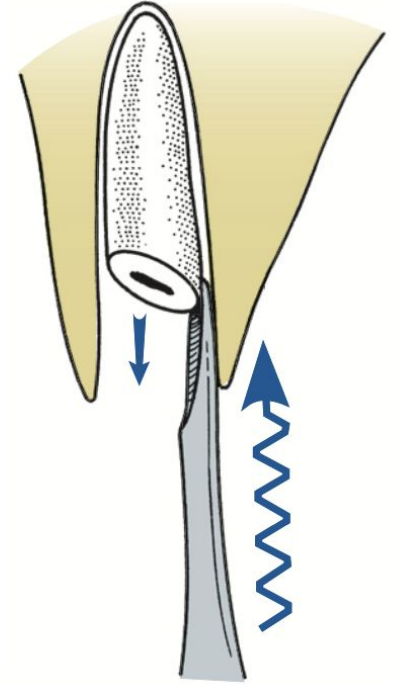
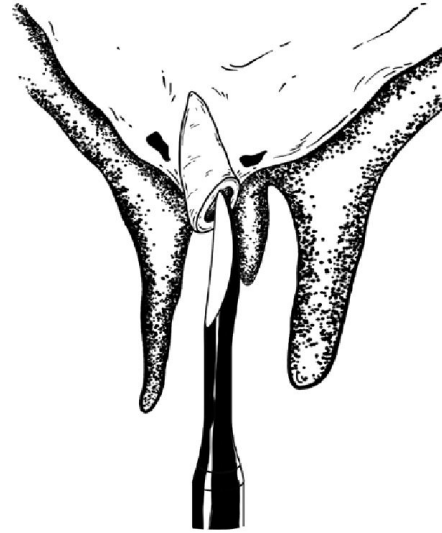
Roots in maxillary sinus

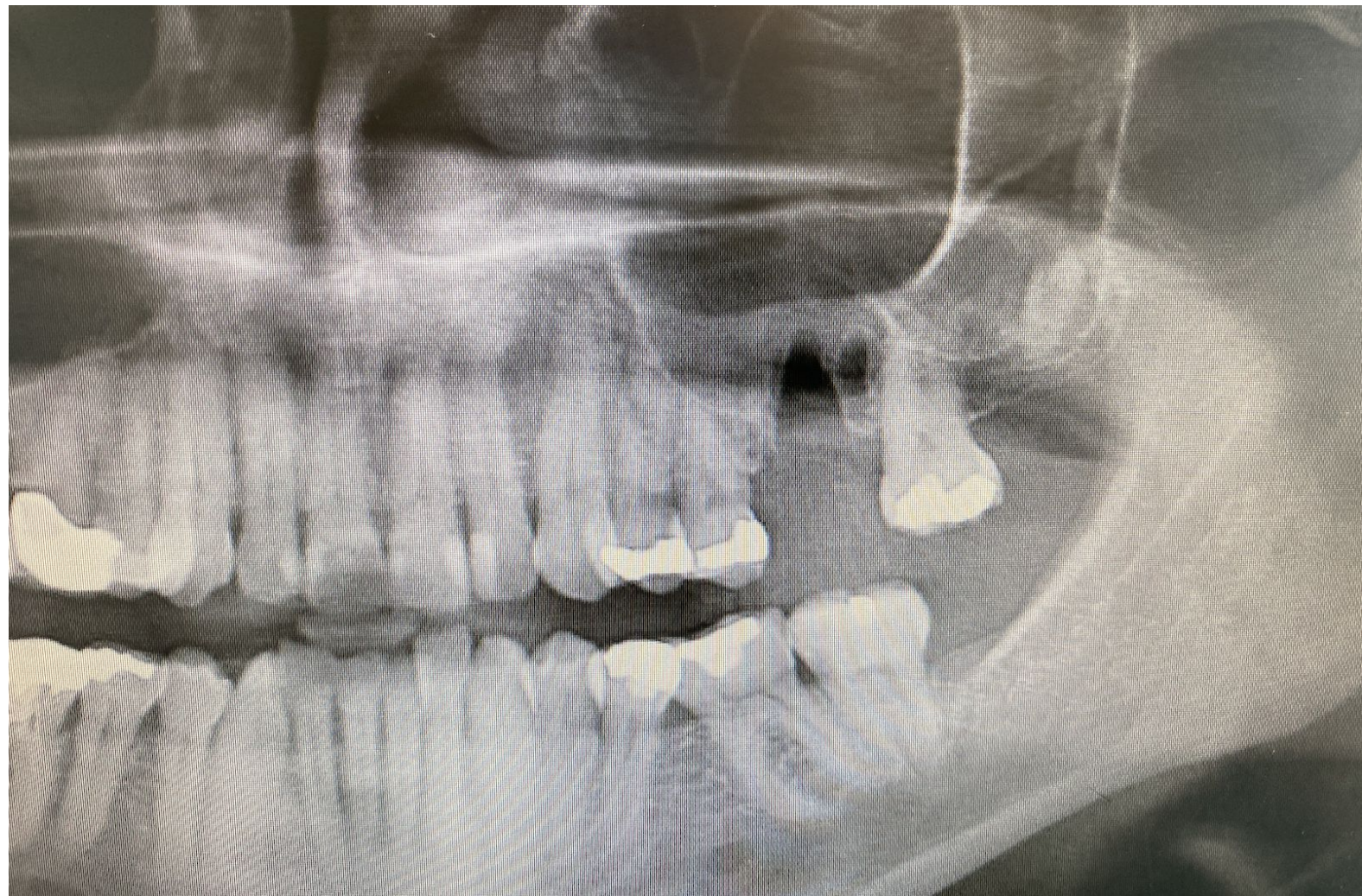
When roots in close proximity to sinus, pushing onto the root itself with luxator → roots in sinus

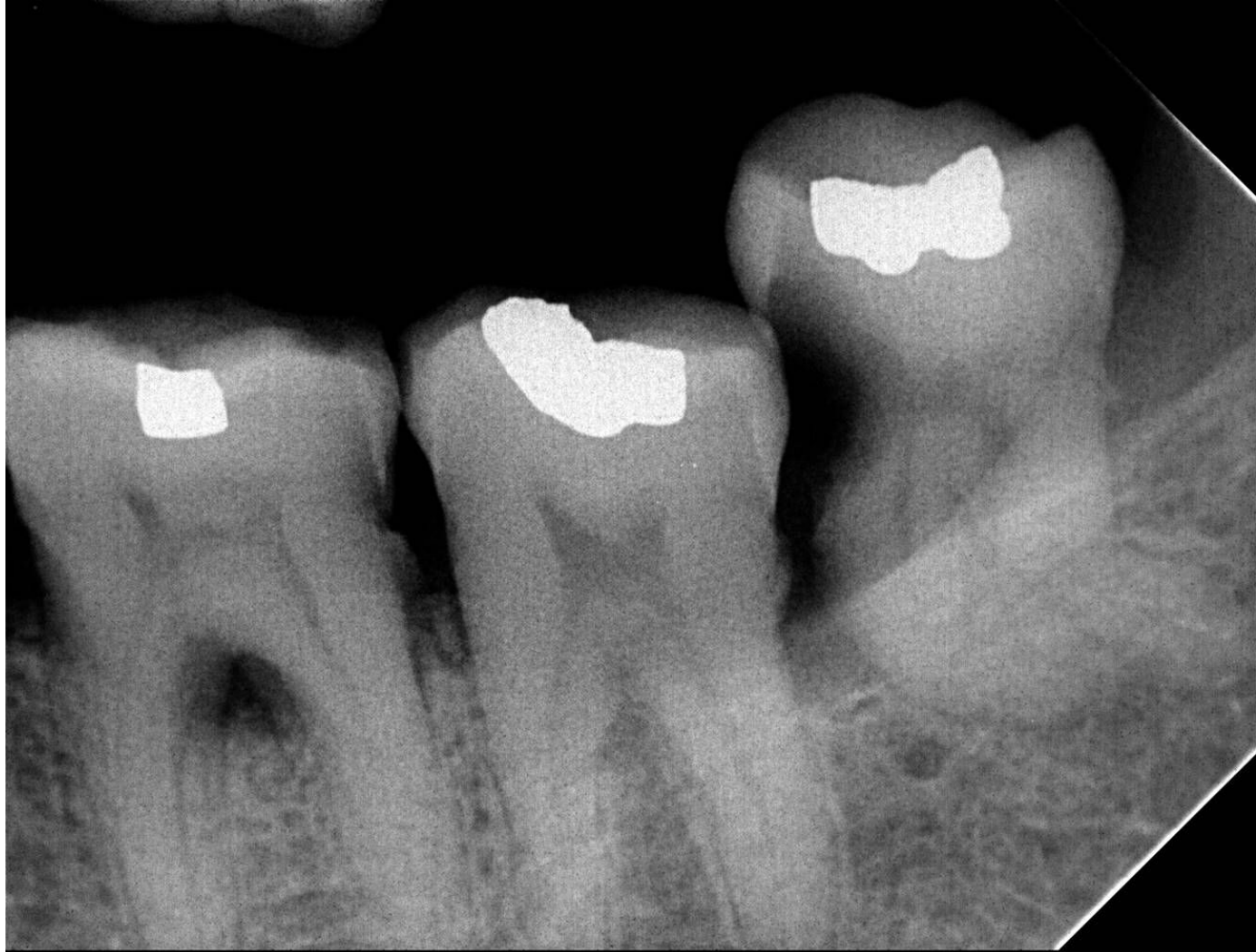Either make space for removal of root by surgically removing bone around the root

Or

Carefully luxating around the root/using cryers to elevate root without pushing into sinus







(T)

References

VISSCHER, S. H., VAN MINNEN, B. & BOS, R. R. 2010. Closure of oroantral communications: a review of the literature. *J Oral Maxillofac Surg*, 68, 1384-91.