

Introduction to Oral and Maxillofacial Surgery

Dr Ven Woo
Dr Ken Lin

2023

Dr Ven Woo

2009-2012: BBiomed with Honors (Melbourne)

2013-2016: DDS (Melbourne)

2017: Dental Resident, Monash Health (Monash Medical Centre and Dandenong Hospital)

RACDS Primaries

2018: OMFS Resident, Royal Dental Hospital of Melbourne

2019-2020: OMS House Dentist, Adelaide Dental Hospital and Royal Adelaide Hospital

2019 - 2022: MBBS (Adelaide)

2019 - 2022: Private (GDP and oral surgery); public (OMFS and Primary Care, Royal Dental Hospital of Melbourne)

2023: Intern (CALHN)

Dr Ken Lin

- 2009-2013: BDS (Otago)
- 2014-2016: Dental House Officer, Palmerston North Hospital, NZ
RACDS Primaries
- 2017-2018: Private Practice (GDP + Oral Surgery), Auckland NZ
- 2018-2019: OMS Senior House Officer, Royal Gwent Hospital, Wales, UK
- 2020: Postgraduate Diploma in Clinical Dentistry (PGDipClinDent) Oral Surgery, Otago
- 2021-2022: OMS House Dentist, Adelaide Dental Hospital, Royal Adelaide Hospital
FRACDS(GDP)
- 2021-present: MBBS V

Overview of AAPDP OMFS series

Lecture 1: Introduction + simple extractions

Lecture 2: Surgical including third molar extractions

Lecture 3: Dental emergencies

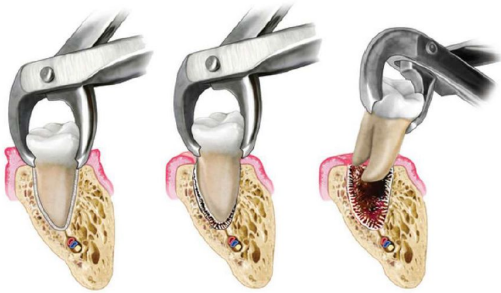Lecture 4: Management of medically compromised patients

Disclaimer

- This talk is aimed to give a practical approach to cases seen in the Oral & Maxillofacial Surgery extraction clinics and potentially in future practice for graduating dentists.
- As accurate as possible (backed by literature) but please do not only rely on this lecture for your exams.
- Contents of the lecture are based on our clinical experience and what we were taught. There may be some discrepancies among preferences and approaches to treatment compared to other clinicians. There are multiple ways to do things.
- The authors of this talk do not accept any responsibility or liability relating to the use of this information.

Recommended Reading

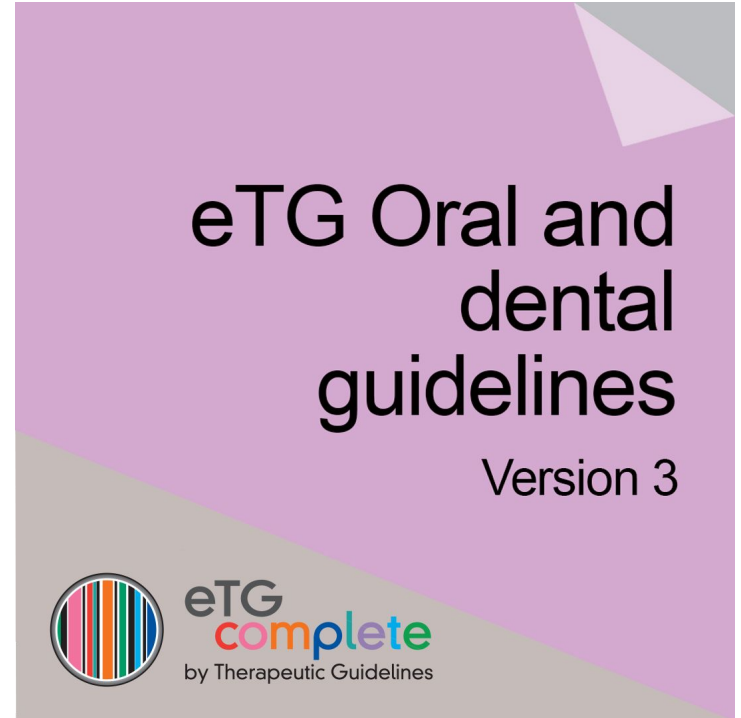
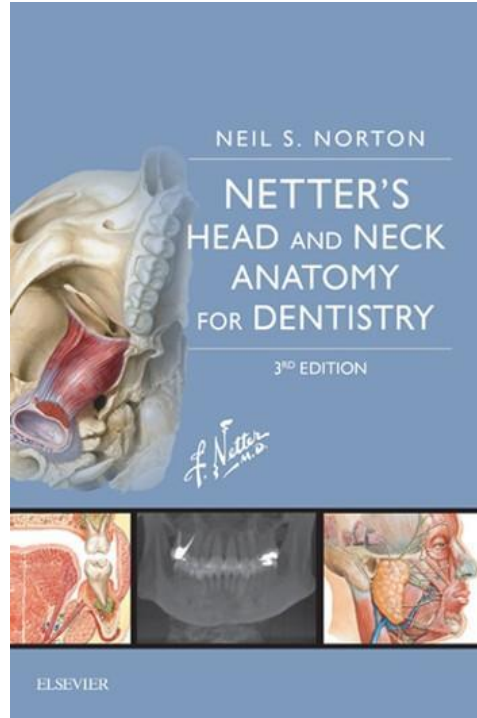
PRINCIPLES OF DENTOALVEOLAR EXTRACTIONS



SETH DELPACHITRA | ANTON SKLAVOS
RICKY KUMAR



WILEY Blackwell



Lecture Overview

Introduction

What is Oral and Maxillofacial
Surgery?

Adelaide OMFS Unit

Assumed knowledge

Local Anaesthesia

How to present a case

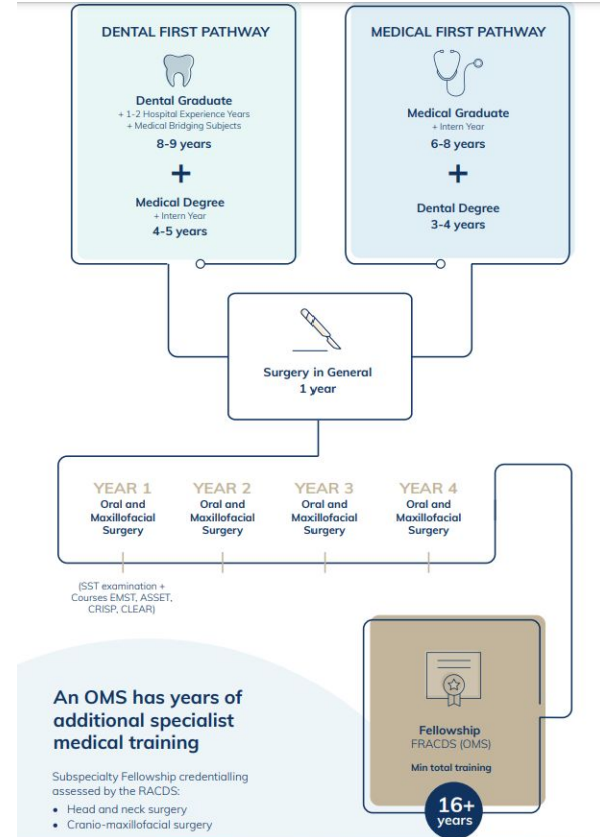
Simple extractions

What is Oral and Maxillofacial Surgery (OMFS)?

Royal Australasian College of Dental Surgeons:

“Oral Maxillofacial Surgery is a challenging specialty that combines dental, medical and surgical knowledge and skills. It requires extensive study in a rigorous training program.

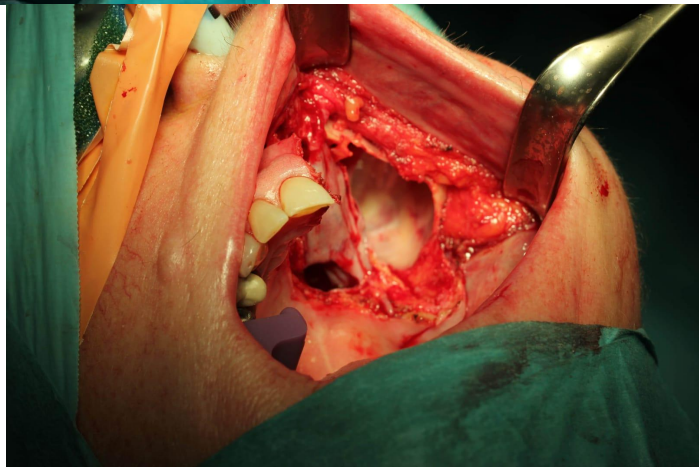
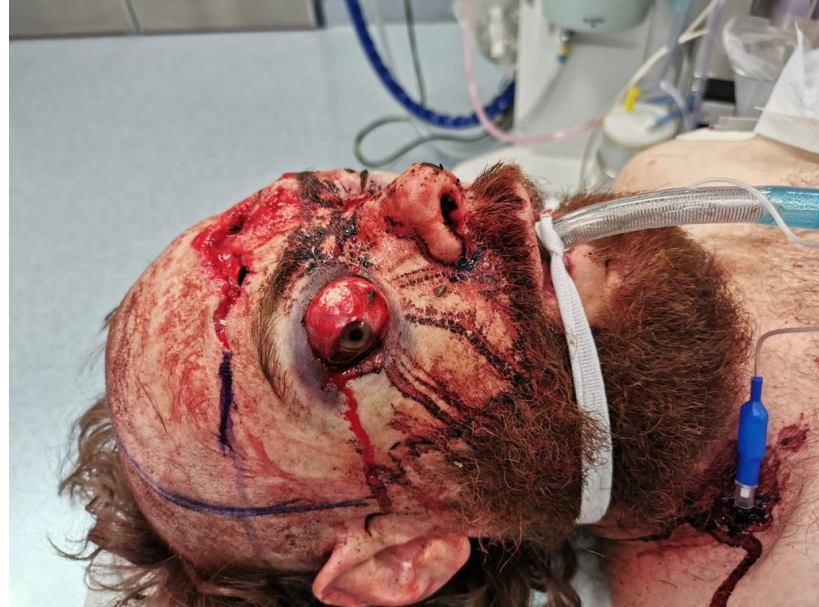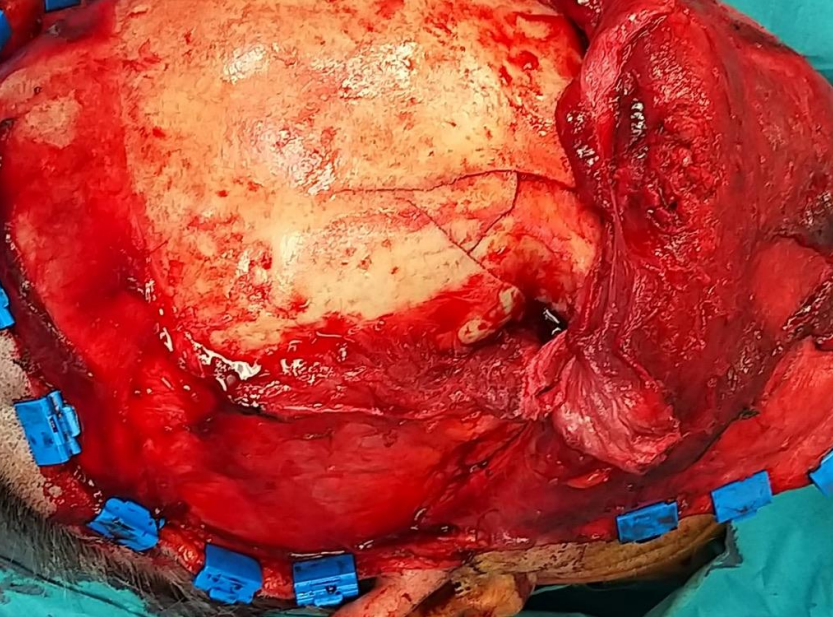
Oral Maxillofacial Surgeons specialise in the oral and maxillofacial regions of the neck and head. They diagnose and treat problematic wisdom teeth, facial pain, and misaligned jaws. They also treat accident victims for facial injuries, carry out reconstructive and dental implant surgery, treat tumors, developmental craniofacial abnormalities of the jaws or facial regions.”



What is Oral and Maxillofacial Surgery (OMFS)?

Areas of surgery:

- Preprosthetic surgery (bone augmentation)
- Oral and dentoalveolar surgery for the removal of impacted and buried teeth, cysts
- Dental implant surgery and bone grafting, to replace missing teeth or stabilize dentures; rehabilitation of patients having undergone surgery for tumors, to retain facial prostheses
- Orthognathic surgery for dentofacial deformities
- Facial trauma surgery for facial bone fractures and related soft tissue injuries
- Reconstructive surgery of the face
- Cleft lip and palate surgery
- Congenital craniofacial deformities
- Facial plastic surgery such as rhinoplasty, rhytidectomy, blepharoplasty, facial implants
- Temporomandibular Joint Disorder (TMJD)
- Snoring and sleep apnea correction surgery
- Tumor and cancer surgery



Adelaide OMFS Unit

Adelaide Dental Hospital - Level 12

- LA extraction clinic
- Elective clinic
- Outpatient clinic

Royal Adelaide Hospital

- GA lists - elective and emergency
- ED

Adelaide OMFS Unit

Head of Unit: Professor Paul Sambrook

Emeritus Professor Alastair Goss

OMFS Consultants

- Dr Janet Scott
- Dr Andrew Cheng
- Dr James Badlani
- Dr Aaron Thomas

OMFS Registrars

- Dr Sanjaya Gamage
- Dr Akash Sivam
- Dr Vishal Bulsara

House OMFS Residents

- Dr Russell Holloway
- Dr Emilija Jensen
- Dr Ruby Richardson
- Dr Elaine Yu

What to expect during your OMFS rotation?

Short time to learn the clinical aspects of oral surgery

Learn how to extract teeth (and hopefully not be scared by it!)

Assist and participate in surgical extractions

How to manage medically compromised patients

Consolidation of patient communication/management skills

Most importantly - have fun, and learn about OMFS!

Expectations of students

Introduce yourself

Leave bags and personal belongings in lockers or in clinic rooms (not OMFS reg room)

Mobile phones on silent and put away

Please wear appropriate clinic clothes - no t-shirts, no bare shoulders, etc

- You will be told to leave if dressed inappropriately

Be involved in all appointments from start to finish

Expectations of students

Clinicians will ask you questions - be prepared! They do not expect you to know all the answers and they are not trying to be harsh. They want you to learn. Try your best!

Be mindful of patient confidentiality - do not discuss cases outside of the unit and NO photographs

Be respectful at all times - department staff have been in the field for a long time

Do not loiter in the corridors

Stay awake during audit (if attending)

Expectations of students

During OPC, elective clinic:

- Introduce yourself to the patient and get permission to observe
- Enter at the beginning of the appointment and stay until the end (including post-op information at the end of a surgical)
- DO NOT leave halfway through to observe another patient (if you need to leave, politely inform the clinician you are with)
- Understand a sterile field (do not touch unless scrubbed) and wear a shielded mask when observing a procedure
- Think of questions during the appointment and write them down in a notebook - only ask the questions once the patient has left
- Learn how to gain informed consent
- DO NOT (at any point) offer suggestions to the operator whilst they are performing surgery (can be perceived as offensive) - pose it as a question once the patient has left

Expectations of students

During elective/emergency GA:

- Read up on the case(s) that you are going to observe
 - Either ask the OMFS registrar
- Know the patient's name and their history
- Introduce yourself to nursing staff at the beginning of the AM/PM list
- In theatre, wear scrubs and red hair net
- Understand a sterile field (do not touch anything blue unless scrubbed) and wear a shielded mask when observing a procedure

Assumed Knowledge

Anatomy

Local anaesthesia

- Anatomy
- Techniques
- Pharmacology

Medical conditions and common medications

Patient communication

Informed consent

Kahoot Break!

An inferior alveolar nerve block on one side will anaesthetise the.....

- A. Contralateral lower lips
- B. Buccal mucosa of ipsilateral 37
- C. Posterior $\frac{1}{3}$ of tongue
- D. Ipsilateral mental nerve

D. Ipsilateral mental nerve

A 70-year old female patient has come in 2 days after an extraction. She has stage 3 kidney disease and has already taken 1000mg paracetamol. What else can she have?

- A. More Paracetamol
- B. Ibuprofen
- C. Aspirin
- D. Oxycodone

D. Oxycodone

What is the technique in extracting a lower incisor?

- A. Mesio-distal movement
- B. Bucco-lingual movement
- C. Rotational movement
- D. Use your fingers

C. Rotational movement

You are doing a full clearance and need to top up LA. The patient's lips are numbness but is now experiencing ringing in his ears. What is this a sign of?

- A. You've numbed the vestibulocochlear nerve
- B. LA overdose
- C. Patient just has hearing issues
- D. They are experiencing auditory hallucinations

B. LA overdose

You are extracting the 37. You have given two IAN blocks. The patient's lips and buccal mucosa are numb, but she is still experiencing pain on the 37. What do you do next?

- A. Do a 3rd inferior alveolar nerve block
- B. Do a lingual nerve block
- C. Inject into the intraligamentary space of the 37
- D. Infiltrate lingual of 37

C. Inject into the intraligamentary space of 37

Case Presentation

I - Identification

S - Situation

B - Background

A - Assessment

R - Recommendation

When seeing patients:

- 3 identifiers
- Confirm reason for presentation
- Focused history
- Medical history, medications, allergies
- Examination
- Assessment of radiographs
- Case presentation including your treatment plan

ISBAR Examples

Patient coming in for extraction

Julie is a 50 year old woman who has been referred from her community dentist in Noarlunga for extraction of the 27. The tooth is carious into the pulp and unsalvageable. This is on a background of osteoporosis, MI 2 years ago with stent placed and hypertension. She takes aspirin, metoprolol and denosumab. Her last denosumab injection was 5 months ago. She has no history of taking bisphosphonates. She has no allergies and is not a smoker.

On examination, the 27 is carious with the distal portion of the crown still intact. This is supported by the OPG/PA, which also shows the roots in close proximity to sinus.

My plan is for extraction today. I have advised her that, along with the other general risks, that she is at risk for MRONJ. To minimise this complication, I plan to pack and suture once the tooth has been extracted and for close reviews in the next 3 months for healing.

Patient coming in for review

Julie is a 50 year old woman who's come in today for a review of the 27 socket. This was extracted one month ago and she has previously been on denosumab.

She's hasn't had any problems from the socket, hasn't felt any pain or discomfort from the socket since 1 week post-operatively. She doesn't report any sharp bone protruding out of her socket or digging into her mucosa.

On examination, there is no extraoral or intraoral swellings. The socket has full mucosal coverage, no purulent discharge and no exposed, necrotic bone around the socket.

My impression is that the socket is healing well with no signs of MRONJ and the plan is to restart her on the denosumab and follow-up in 3 months time.

Obtaining Consent

Usually verbal for simple extractions; recommended to have written consent for surgical extractions

Explain why the tooth requires extraction and if there are other treatment options

Explain the procedure (simple vs. surgical)

Risks associated with extractions:

Pain

Bleeding

Bruising

Infection

Swelling

Damage to adjacent teeth

Temporary +/- permanent numbness to nerve (if in close proximity)

Oro-antral communication (if close to sinuses)

- Dislodged roots into sinuses/fascial spaces

Osteonecrosis of the jaw

Potential to refer to specialist

Local Anaesthesia

Dosage calculation

- Max dosage for patient, how to calculate this based on type of LA (refer to eTG)

Infiltration vs. block

Technique - no fingers!

Remember to aspirate

Adjunct methods of LA

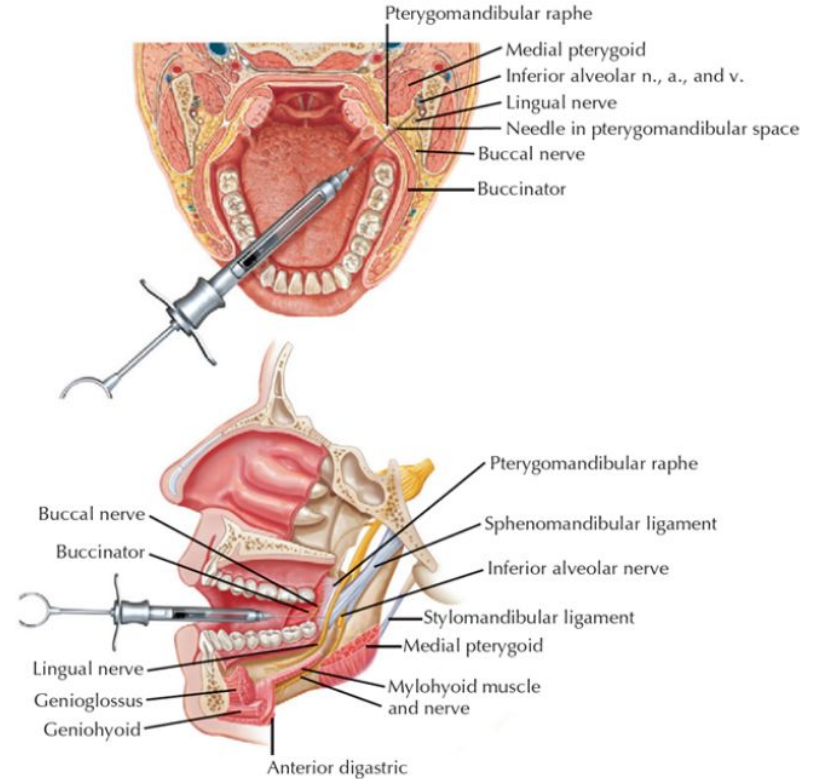
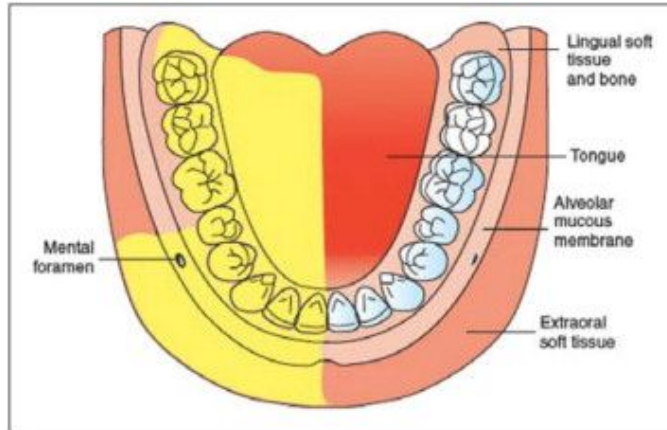
- Intraligamentary injection
- Intrapulpal injection

Local Anaesthesia

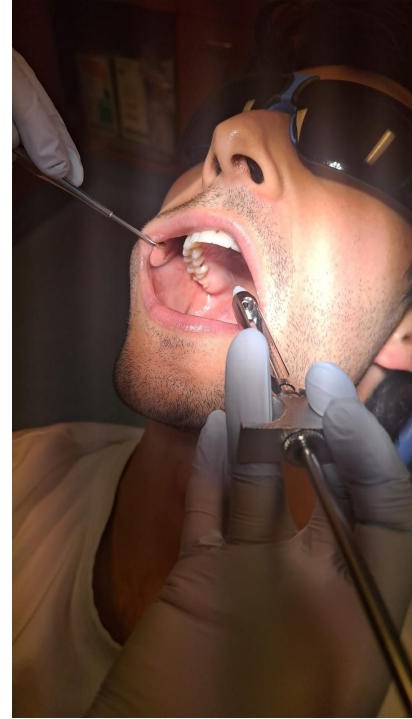
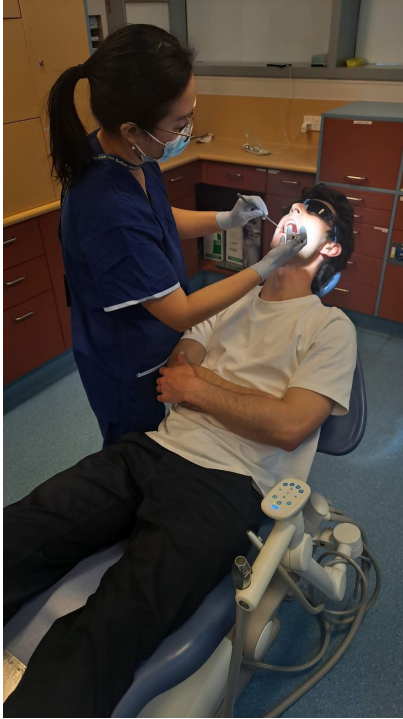Pterygomandibular space

- Injection of LA into this space will affect the IAN and lingual nerves
- Will anaesthetise the mandible excluding the buccal mucosa and skin

?lingual block



LA Technique - Palatal Infiltration



LA – Side Effects and Toxicity

Local effects

- Neuralgic-type pain
- Haematoma
- Transient or permanent nerve injury from physical trauma or visible bruising
- Needle breakage
- Transient facial paralysis
- Necrotising sialometaplasia

Systemic effects

- Anxiety
- Dizziness
- Restlessness
- Tinnitus
- Diplopia
- Tremors
- Convulsions
- LOC
- Bradycardia
- Cardiovascular collapse, cardiac arrest

Simple Extractions

When to consider extraction?

Gross caries

Advanced periodontal disease

Fracture

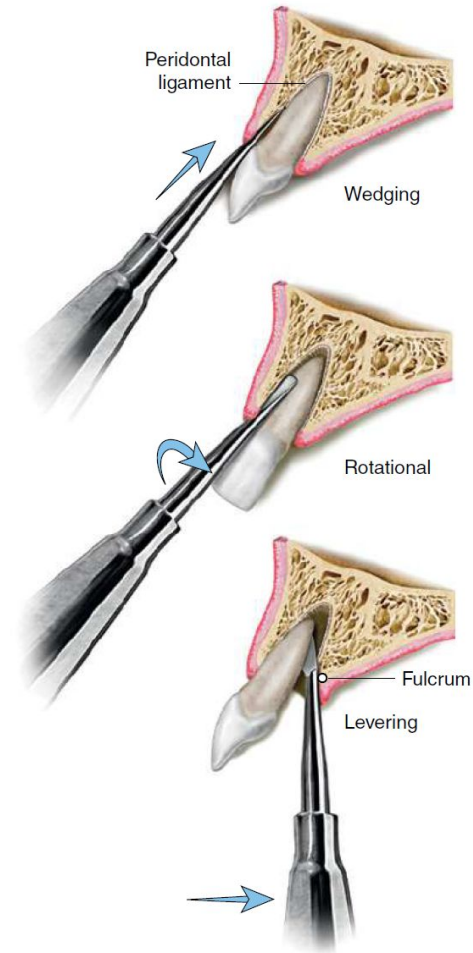
Orthodontic extractions

Dental management for oncology patients or anti-resorptive treatment


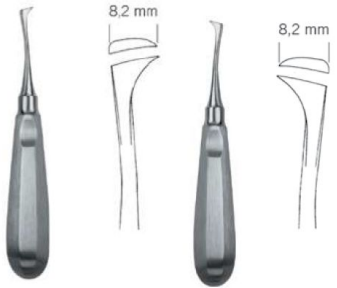

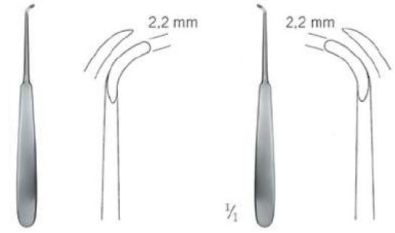

Armamentarium

Elevators and luxators

- Used to apply unidirectional force on a tooth to break the PDL
- Biomechanical principles
 - Wedging
 - Rotational
 - Levering
- General principles
 - Avoid excess, uncontrolled forces
 - Used between tooth and alveolar bone
 - Ensure a stable purchase point in which the elevator can engage
 - Use the fingers of the non-dominant hand as a protective mechanism on the buccal and lingual/palatal alveolar plates



Armamentarium

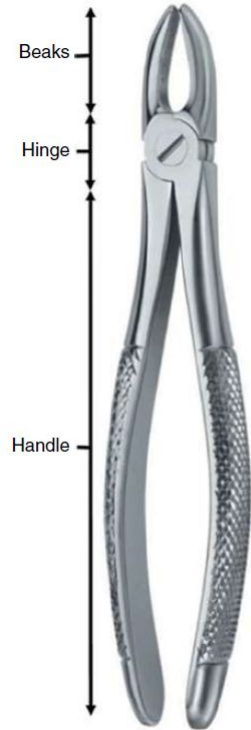
Elevator	Image	Features	Uses	Elevator	Image	Features	Uses
Luxator/ periotome		Straight shank Sharp, curved tip Available in various widths (3 mm, 5 mm)	Disruption of periodontal ligament Expansion of alveolar socket Gentle mobilisation of tooth Elevation of tooth roots	Cryer (Left, Right)		Angled, triangular tip with sharp end	Gripping a point of application on a tooth to provide strong directional force
Coupland's No. 2 Gouge		Straight shank Blunt, curved tip	Mobilisation of teeth	Warwick-James (Left, Right)		Angled, curved, rounded 'golf club' tip	Gripping a point of application on a tooth to provide moderate directional force
				Root Pick		Thin, angled shank Small, sharp, straight tip with slight curvature	Access to apical areas of fractured roots to manoeuvre between bone and tooth root, in order to deliver a light extraction force

Armamentarium

Forceps

- Allows for slow expansion of the bony socket, mobilise the tooth along its strongest axis and grasp and deliver the tooth
- General principles
 - Hold the instrument correctly using the palm of the hand and stand in the correct position to maximise the biomechanics of the shoulder and elbow
 - Beaks should be against the CEJ
 - Balance forces appropriately

Armamentarium



Forceps	
Upper straights	<p>Diagram of upper straight forceps. The beak length is indicated as 3.2 mm. The diagram shows the forceps in a closed position and a detailed view of the beak tip.</p>
Upper universal	<p>Diagram of upper universal forceps. The beak length is indicated as 4.6 mm. The diagram shows the forceps in a closed position and a detailed view of the beak tip.</p>
Upper molar (left)	<p>Diagram of upper molar (left) forceps. The beak length is indicated as 7.6 mm. The diagram shows the forceps in a closed position and a detailed view of the beak tip.</p>
Upper molar (right)	<p>Diagram of upper molar (right) forceps. The beak length is indicated as 7.6 mm. The diagram shows the forceps in a closed position and a detailed view of the beak tip.</p>

Forceps	
Lower universals	<p>Diagram of lower universal forceps. The beak length is indicated as 3.1 mm. The diagram shows the forceps in a closed position and a detailed view of the beak tip.</p>
Lower hawks	<p>Diagram of lower hawk forceps. The beak length is indicated as 5.9 mm. The diagram shows the forceps in a closed position and a detailed view of the beak tip.</p>
Cowhorn	<p>Diagram of cowhorn forceps. The beak length is indicated as 1.8 mm. The diagram shows the forceps in a closed position and a detailed view of the beak tip.</p>

Risks and complications

General:

- Pain
- Infection
- Bleeding
- Bruising
- Swelling
- Dislodgement of restoration
- Adjacent tooth damage
- Tooth aspiration/ingestion
- Instrument fracture
- Dentoalveolar fracture
- Soft tissue laceration/burns
- Further treatment by OMFS

Medical considerations:

- Uncontrolled bleeding
- MRONJ
- ORNJ
- Delayed healing
- Adrenal crisis/thyroid storm

Risks and complications

Maxillary dentition:

- Oroantral communication (OAC)/oroantral fistula (OAF)
- Dislodgement of tooth fragment into maxillary sinus
- Maxillary tuberosity fracture

Mandibular dentition:

- IAN/lingual nerve injury
- Mental nerve injury
- Mandible fracture

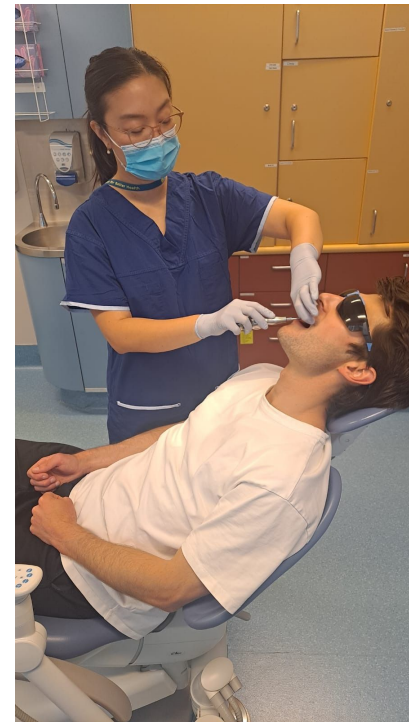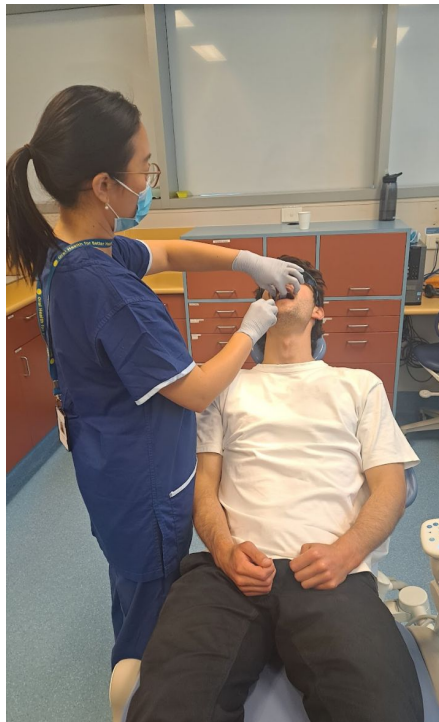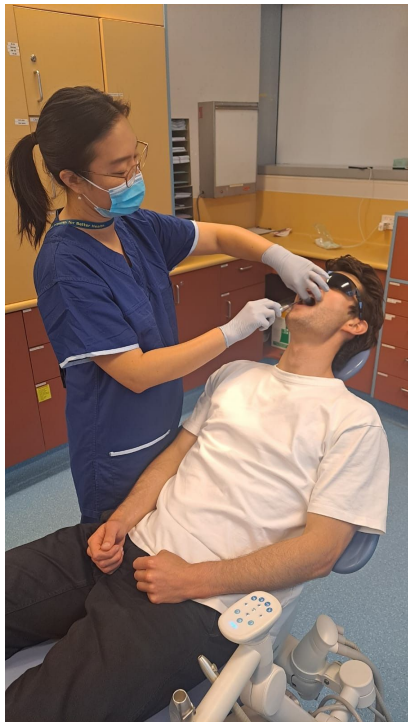Checklist

Assess difficulty

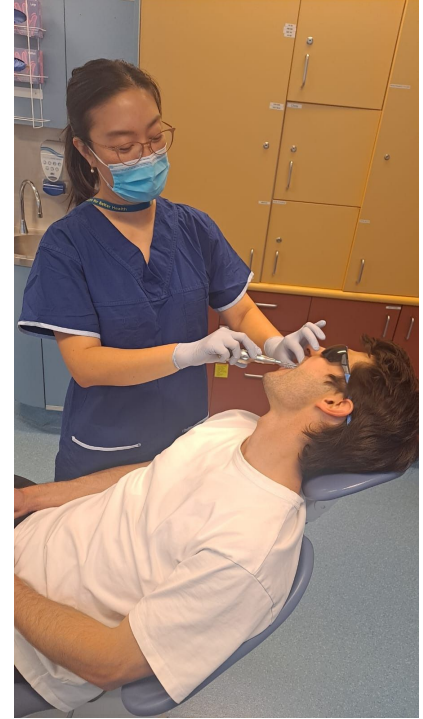
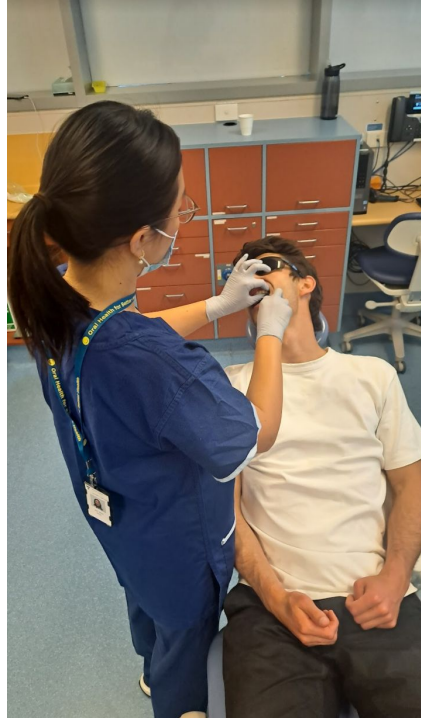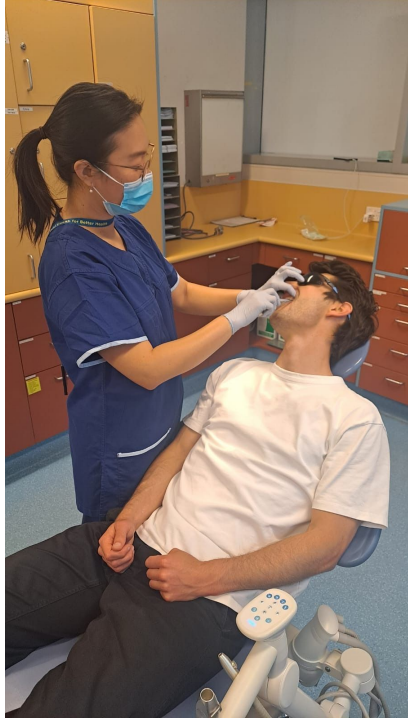Obtain consent - verbal +/- written

Final check - confirm tooth number and location with radiograph

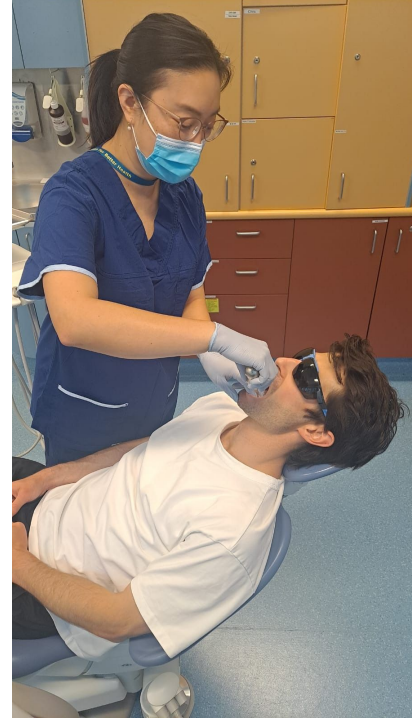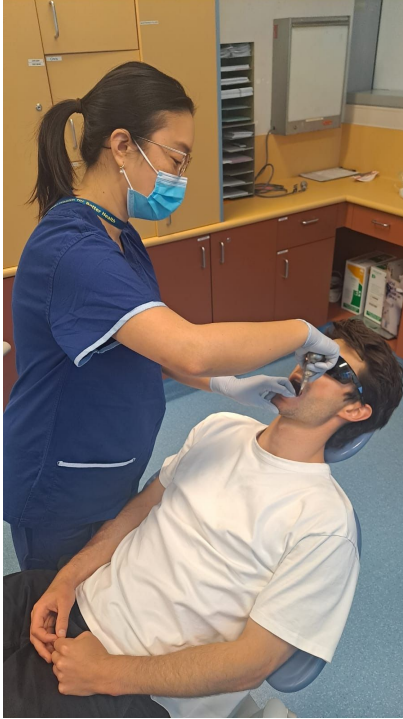Positioning - Q1



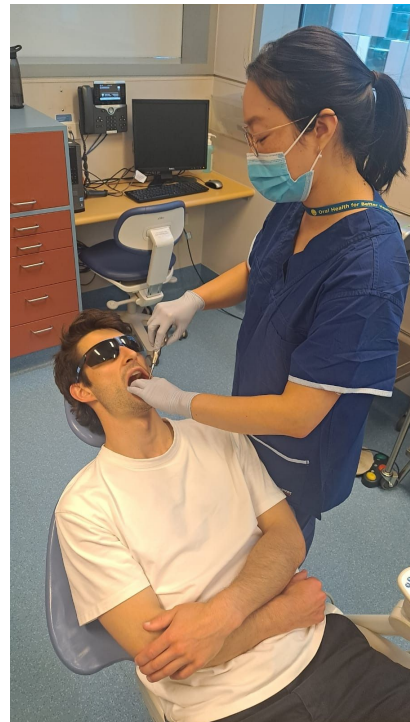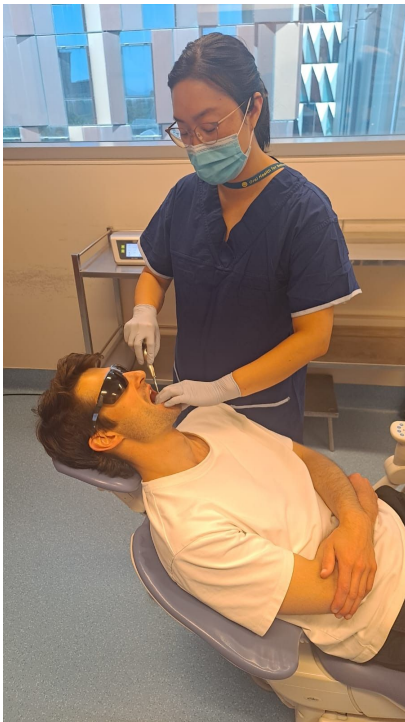Positioning - Q2



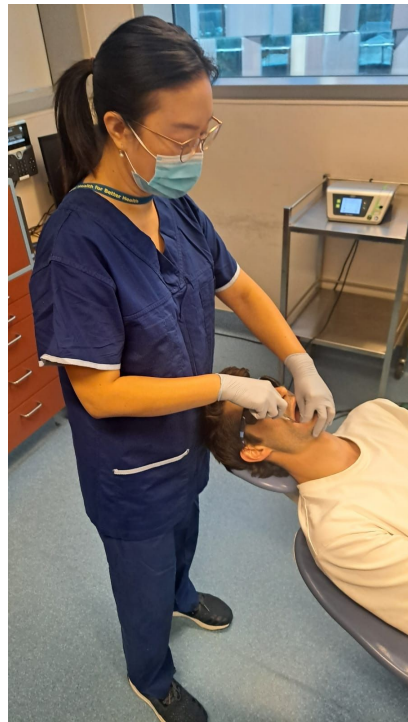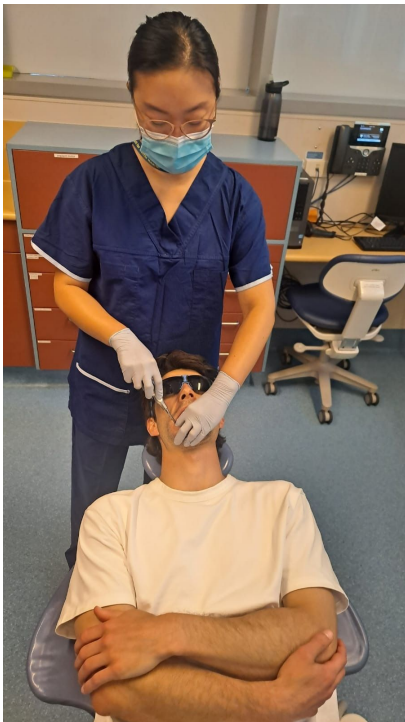Positioning - Q3



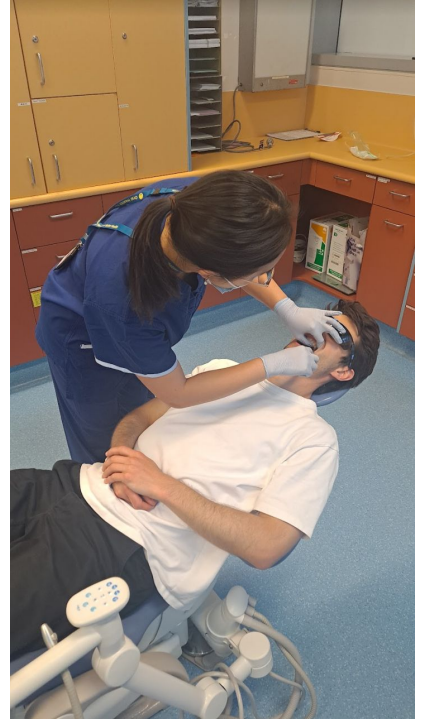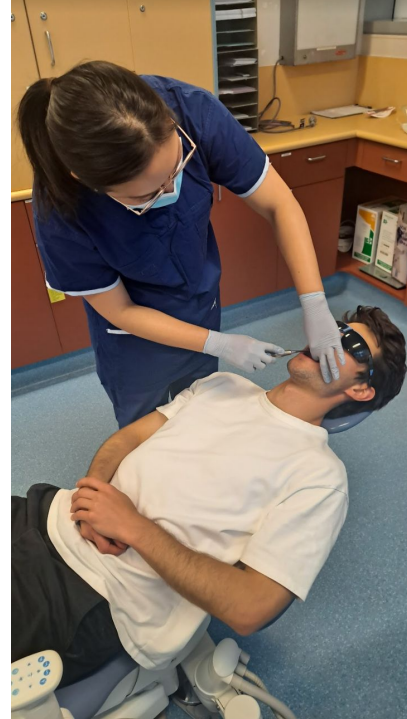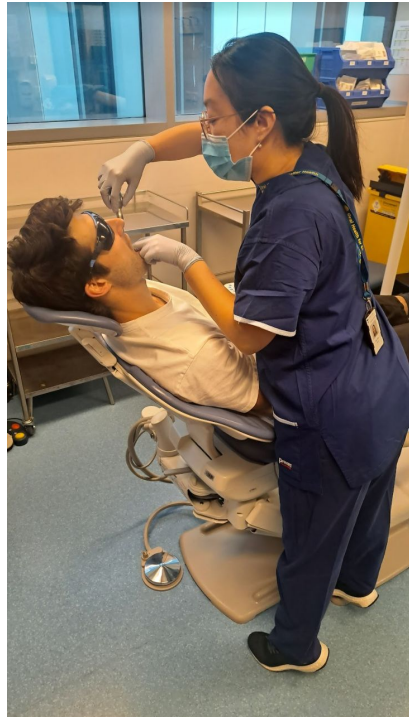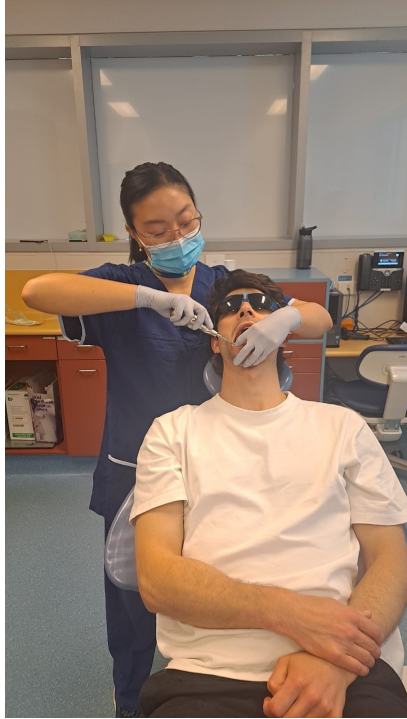Positioning - Q3



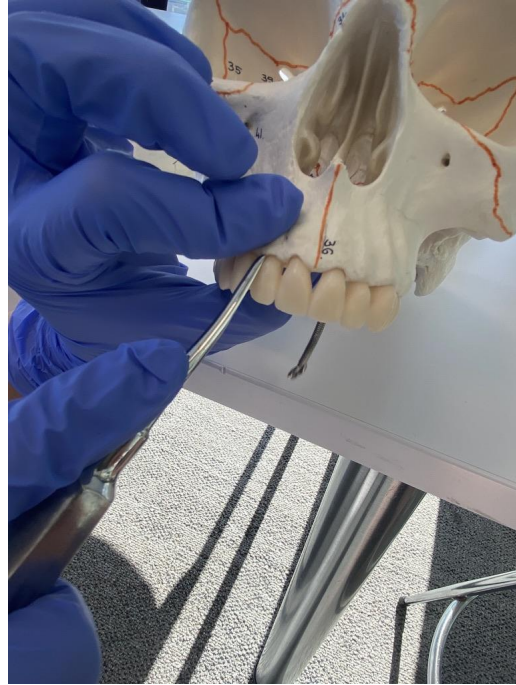
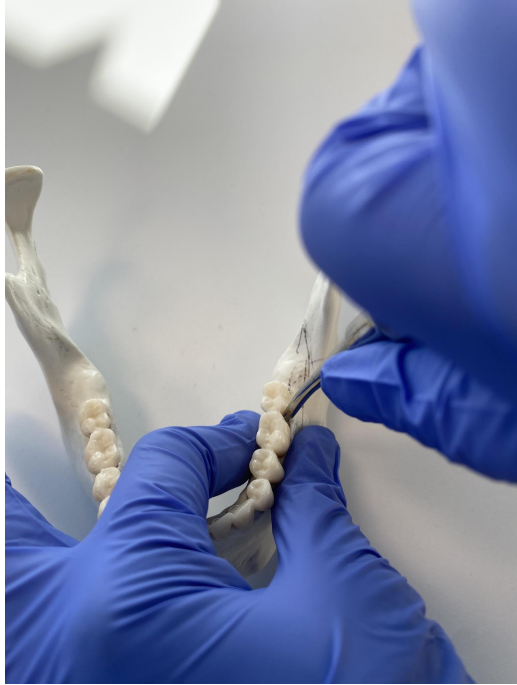Positioning - Q4



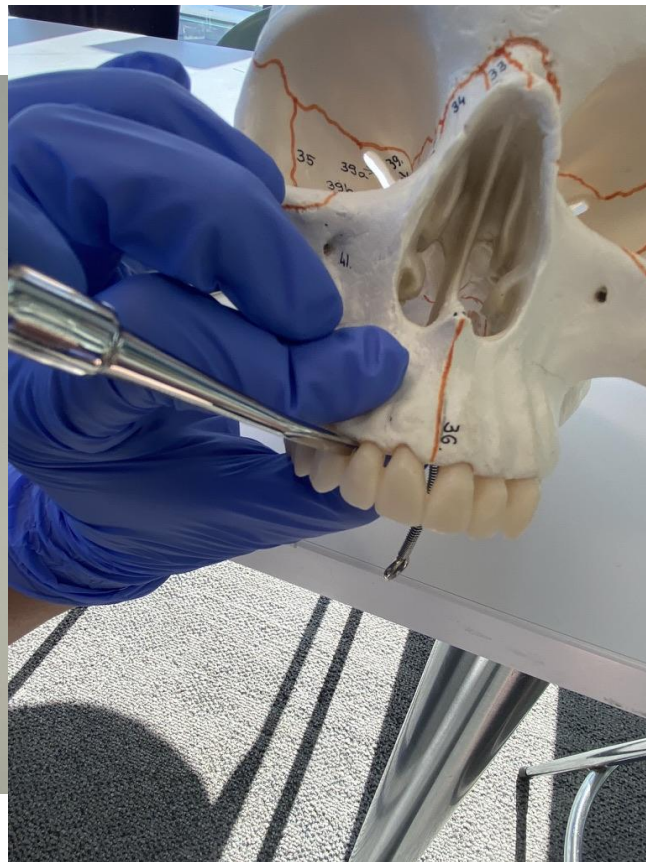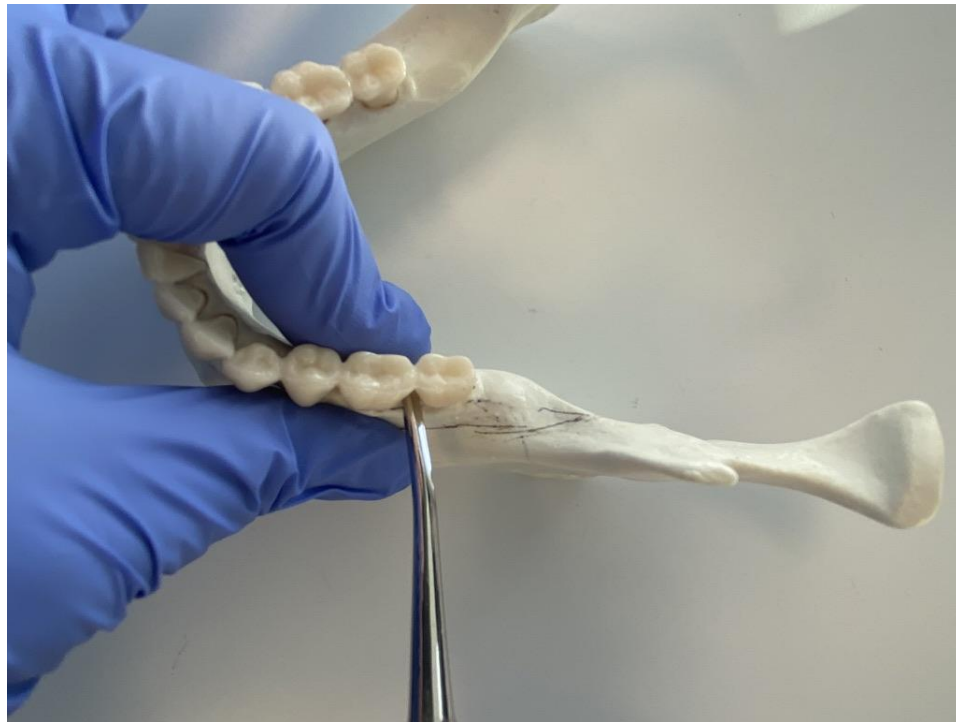Incorrect Positioning



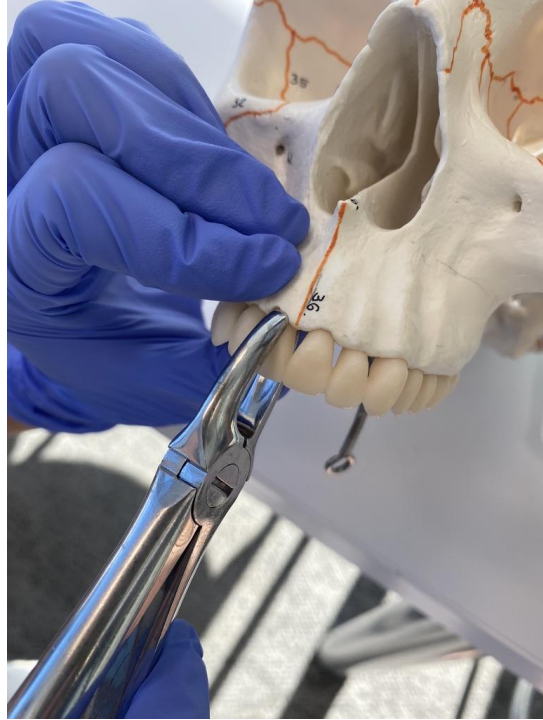Technique: Luxating



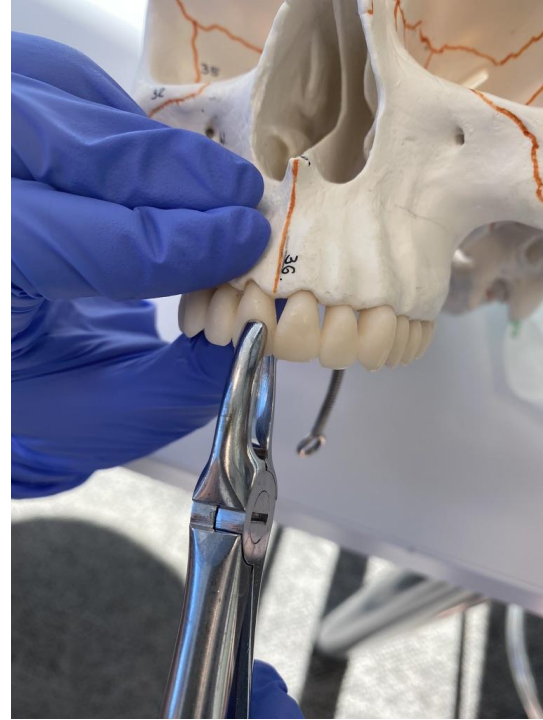Technique: Elevating



Technique: Forceps

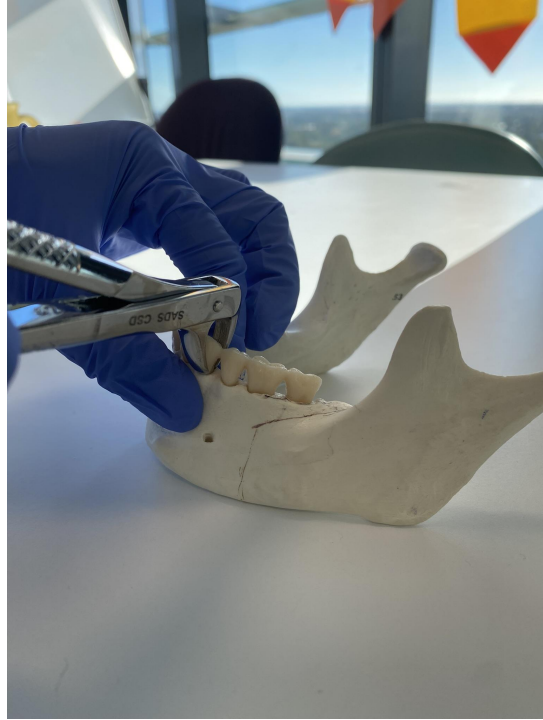

Correct technique

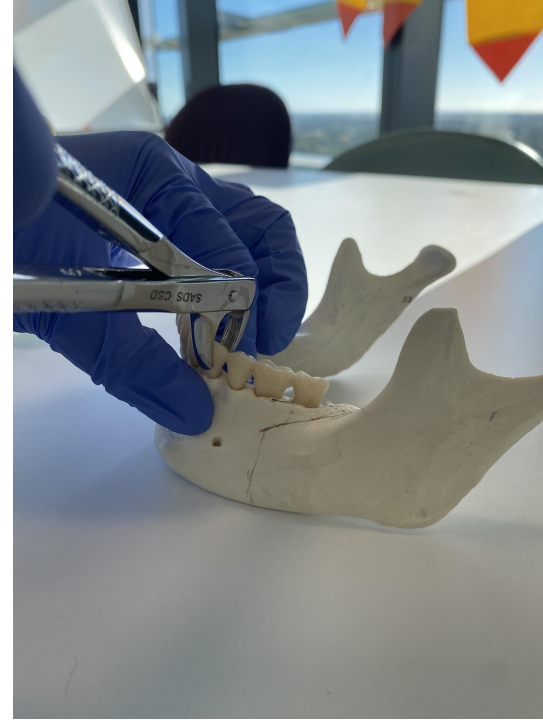

Incorrect technique

Technique: Forceps



Correct technique



Incorrect technique

Technique: Maxillary Incisors

Anatomy: straight root

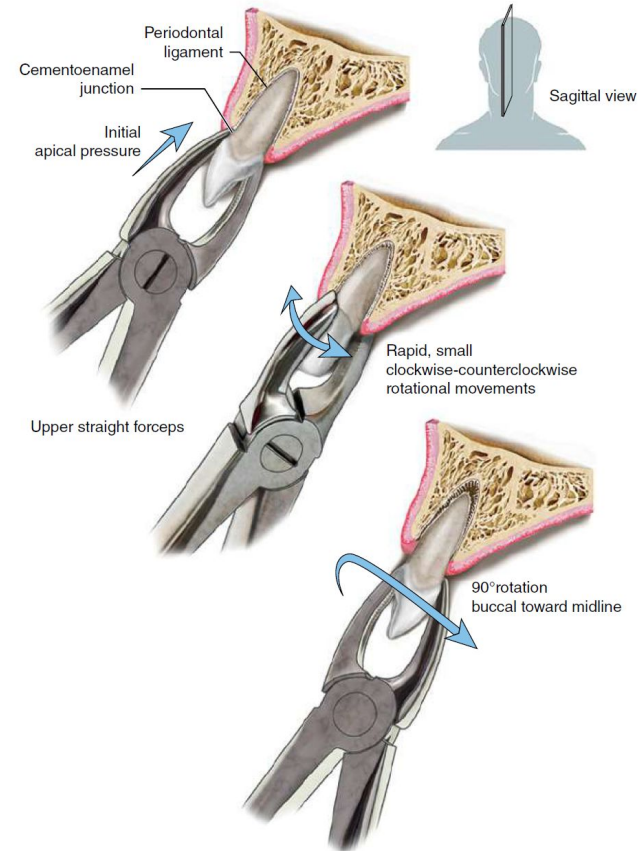
Considerations: fracture of alveolar bone
(prosthetic rehabilitation)

LA: labial and palatal infiltration

Equipment: straight elevator, upper straight forceps

Elevation: straight elevator to mesial and distal areas, wheel-and-axle motion to expand PDL

Delivery: apical pressure; rapid, small clockwise-counterclockwise rotational movements



Technique: Maxillary Canine

Anatomy: long root, thick buccal bone, reduced PDL space

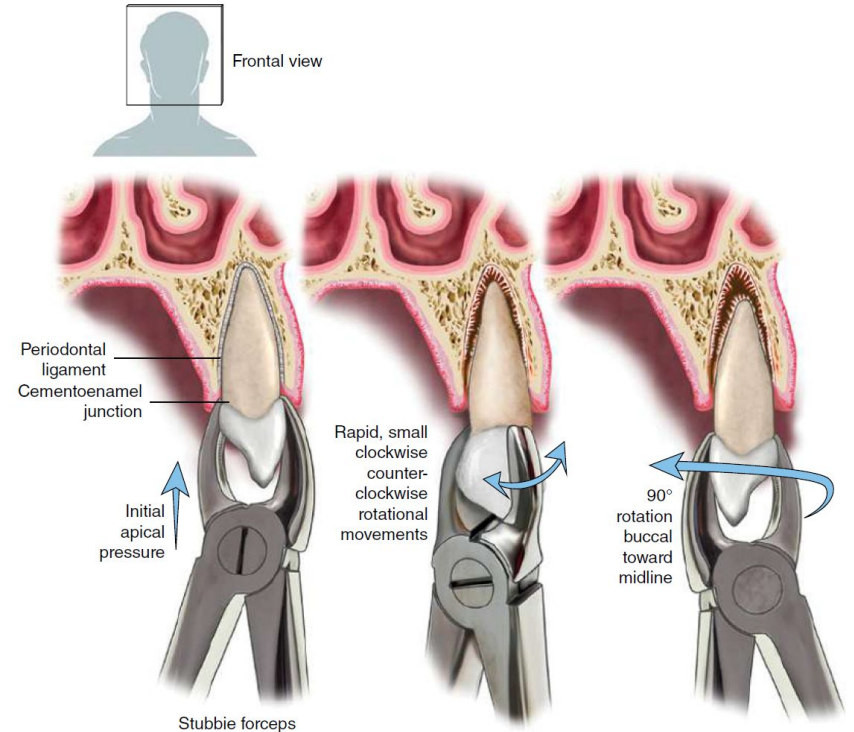
Considerations: buccal alveolar fracture

LA: labial and palatal infiltration

Equipment: straight elevator, upper straight forceps, stubbies

Elevation: straight elevator to mesial and distal areas, wheel-and-axe motion to expand PDL

Delivery: apical pressure; rapid, clockwise-counterclockwise rotational movements. Rotate the crown 90° to deliver.



Technique: Maxillary Premolars

Anatomy: two roots (buccal and palatal) - fused or separate

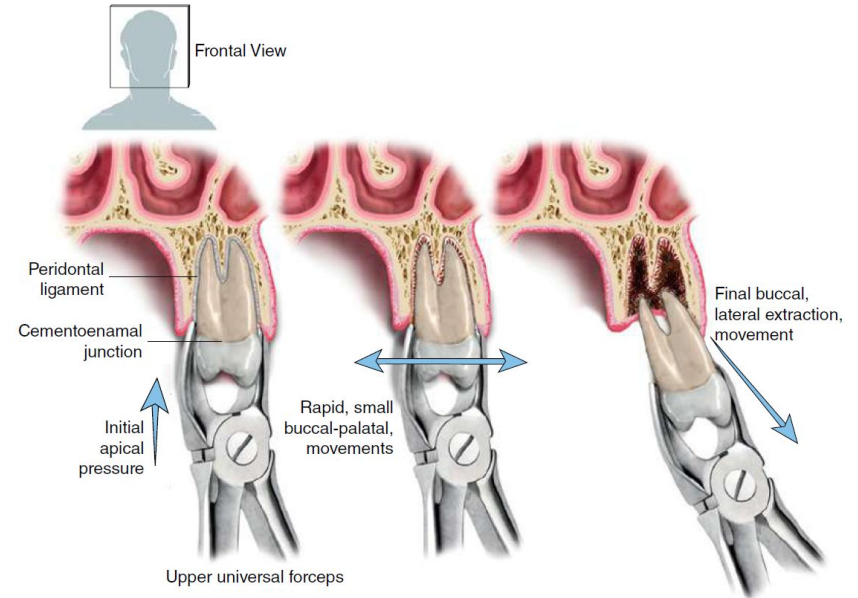
Considerations: buccal alveolar fracture

LA: buccal and palatal infiltration

Equipment: straight elevator, upper universal forceps

Elevation: straight elevator to mesiobuccal aspect, wheel-and-axle motion to expand PDL and push the tooth distally

Delivery: apical pressure; rapid, buccal-palatal movements. Final buccal movement to deliver the tooth laterally



Technique: Maxillary Molars

Anatomy: multiple roots, proximity to maxillary sinus

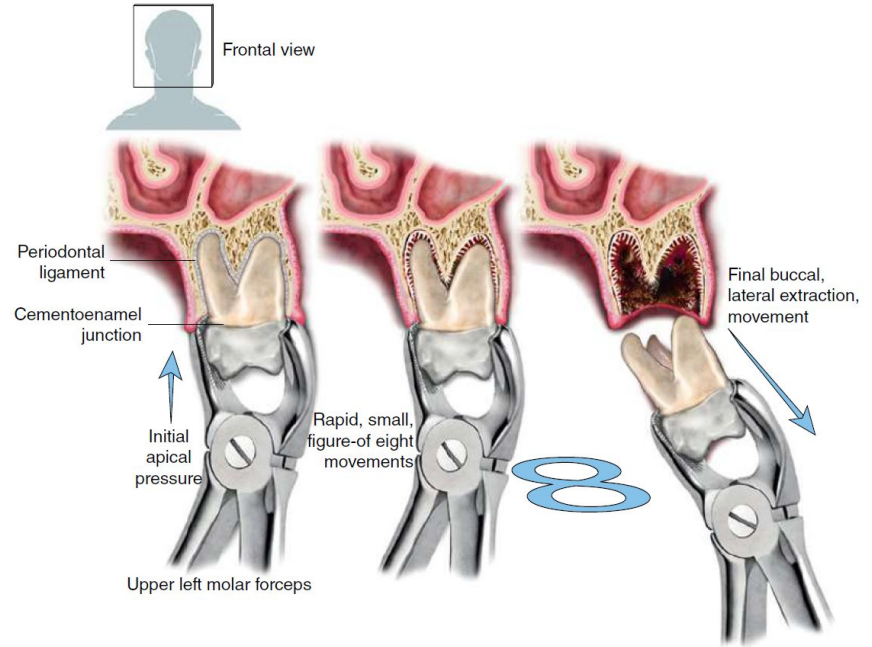
Considerations: lone standing molar, age of patient (> 40 yo), pneumatization of maxillary sinus, OAC, risk of displacement of tooth/root into maxillary sinus, tuberosity fracture

LA: buccal and palatal infiltration

Equipment: straight elevator, upper right/left molar forceps, +/- other elevators as necessary

Elevation: straight elevator to mesiobuccal aspect, wheel-and-axe motion to expand PDL subgingivally

Delivery: apical pressure; buccal-palatal movements, final buccal movement to deliver tooth



Technique: Mandibular Incisors

Anatomy: straight, single root

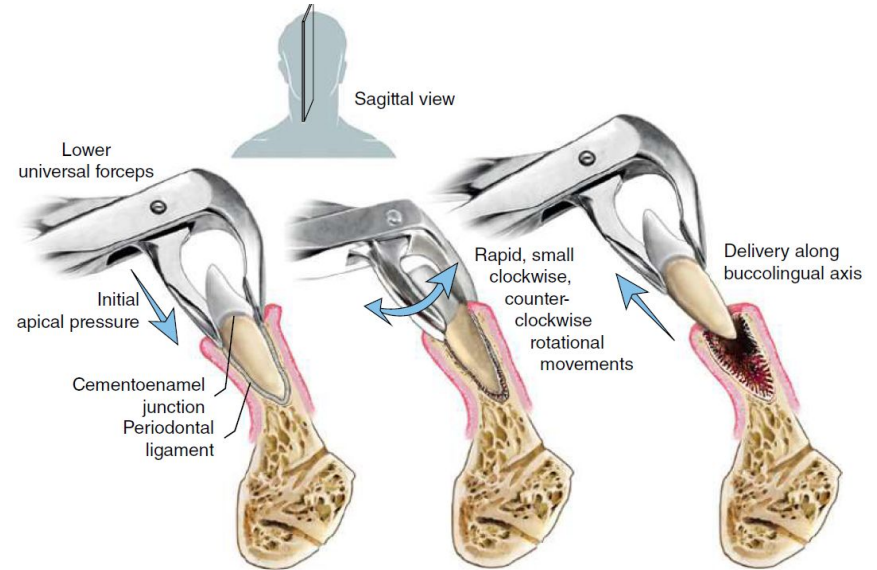
Considerations: FOM, vital structures (neurovascular)

LA: IAN/lingual block + infiltration; mental nerve block; infiltrations (only if periodontally compromised)

Equipment: straight elevator, lower universal forceps, lower root forceps

Elevation: straight elevator to mesial and distal areas, wheel-and-axle motion to expand PDL

Delivery: apical pressure; rapid, small clockwise-counterclockwise rotational movements



Technique: Canines and Premolars

Anatomy: long root, thick buccal and lingual alveolar bone, reduced PDL space, mental foramen

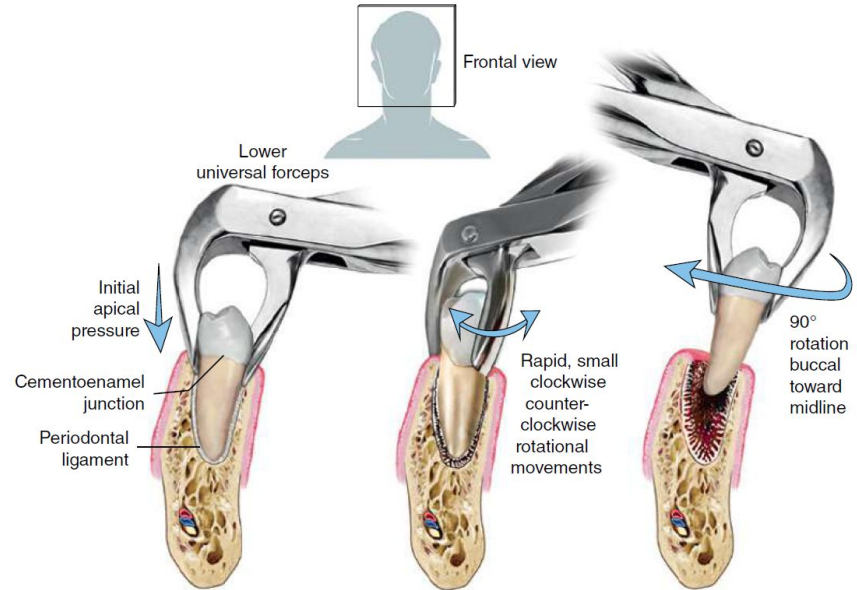
Considerations: buccal alveolar plate fracture

LA: IAN block +/- infiltration

Equipment: straight elevator, lower universal forceps

Elevation: straight elevator to mesial and distal areas, wheel-and-axle motion to expand PDL

Delivery: apical pressure; rapid, small clockwise-counterclockwise rotational movements. Rotate the crown 90° to deliver.



Technique: Mandibular Molars

Anatomy: multiple roots, proximity to IAN canal

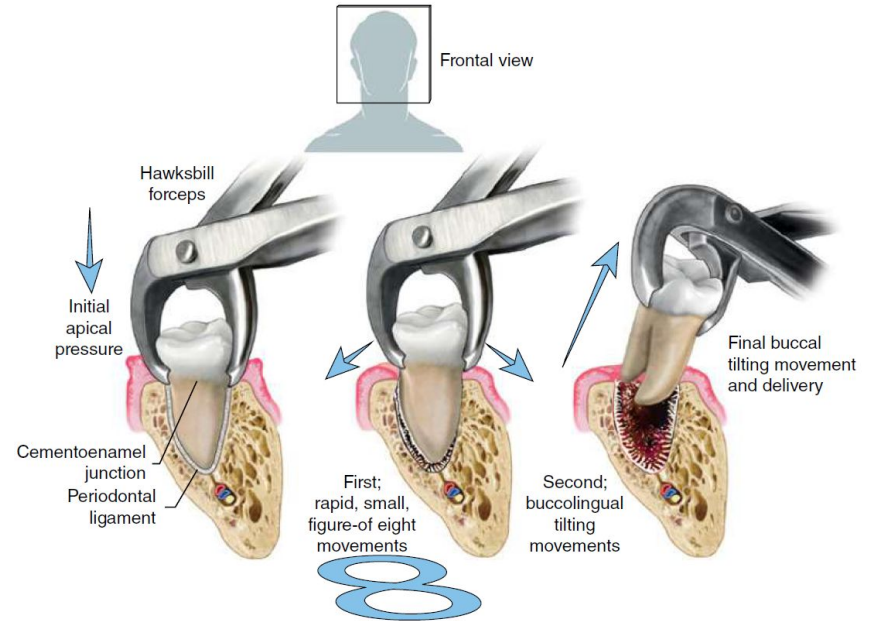
Considerations: IAN injury, bone quality/quantity, buccal mucosa

LA: IAN block, long buccal block

Equipment: straight elevator, Hawksbill forceps, cowhorns

Elevation: straight elevator to mesial and distal areas, wheel-and-axe motion to expand PDL

Delivery: apical pressure; rapid, small buccolingual movement. Buccal tilting movement to deliver with Hawksbill. Crushing force to wedge cowhorn into furcation of the tooth to fracture crown between mesial and distal roots, then deliver buccally



Assessment after extraction

Assess tooth to ensure tooth completely removed

Flush socket with saline

Examination of socket for bleeding, alveolar bone fracture, soft tissue trauma

+/- compression of socket

Haemostasis - ensure patient has stopped bleeding before D/C

- Pressure + gauze
- Adjuncts

Open disclosure regarding intraoperative complications

Postoperative information

- Analgesia
- ?ABx

Postoperative instructions

Bleeding:

- Reassure patient bleeding will occur, pressure with gauze to achieve HA

Pain:

- Paracetamol +/- ibuprofen
- ?Opioids

Function:

- Eat and drink but avoid hot/hard foods and drinks due to anaesthesia
- No rinsing or spitting for 24 hours

Oral hygiene:

- Brush teeth the next day
- Saltwater/chlorhexidine mouthwash D1 postoperative

Swelling:

- Ice packs within the first 24 hours

**Sinus precautions:

- No negative pressure: no nose blowing for 2/52, no smoking, no wind instruments, no drinking through a straw
- Sneeze with an open mouth
- Broad spectrum ABx
- Nasal decongestant
- Avoid swimming 4/12, avoid strenuous exercise 1/52
- Bleeding through the nose is not uncommon
- Review 2-4/52

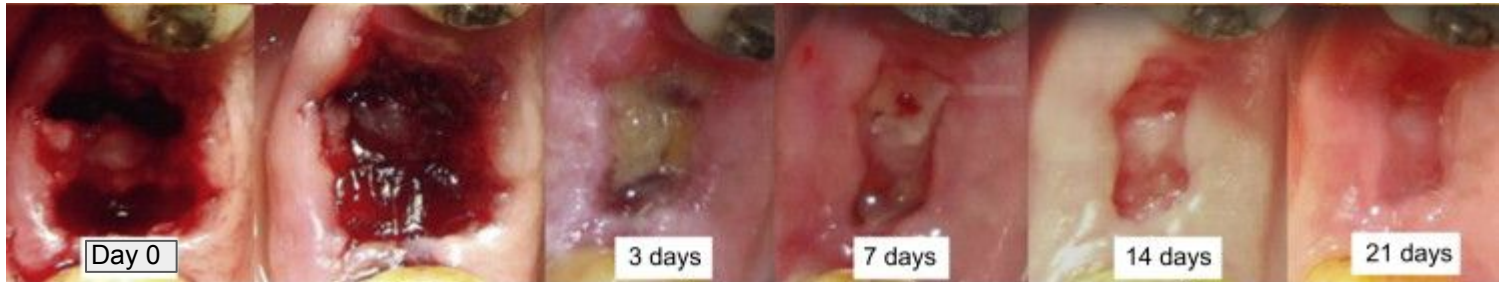Postoperative assessment

Review

- 1-2/52 in low risk patients with no medical comorbidities
- D1 postoperative phone call, followed by 1-2/52 in patients with medical comorbidities or bleeding risk

Timing of healing

- Soft tissue vs. hard tissue



Complications

Intraoperative complications

Lip burn and lacerations

Damage to adjacent teeth or restorations

Mandible fracture

Tooth aspiration or ingestion

Instrument fracture

Intraoperative bleeding

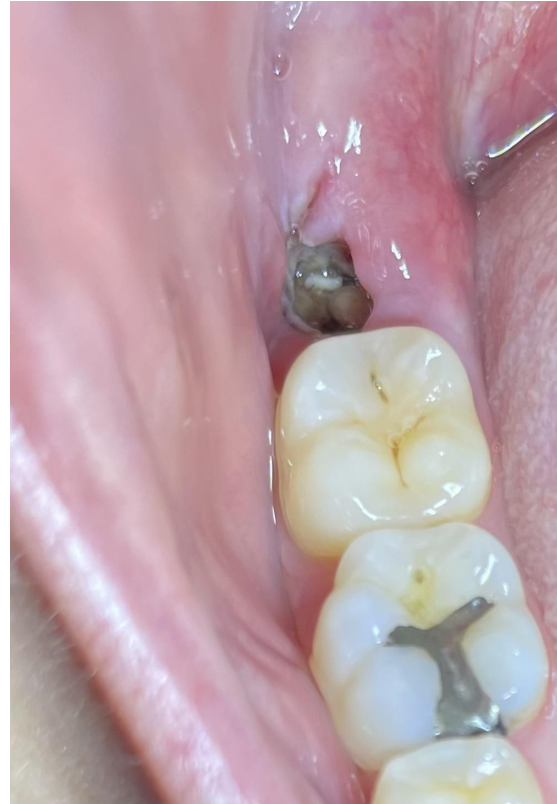
Oroantral communication*

Dentoalveolar fracture

Postoperative complications

Alveolar osteitis (dry socket)

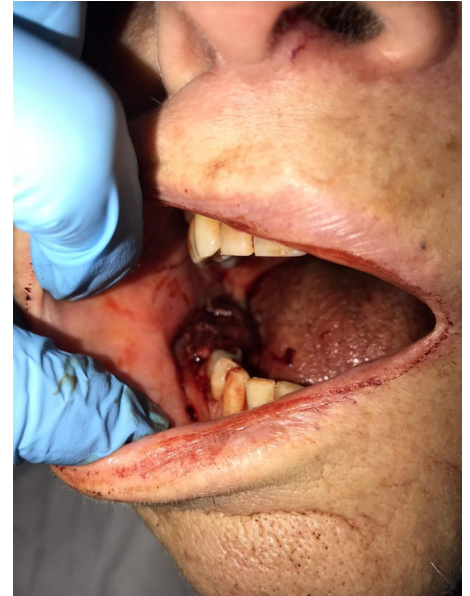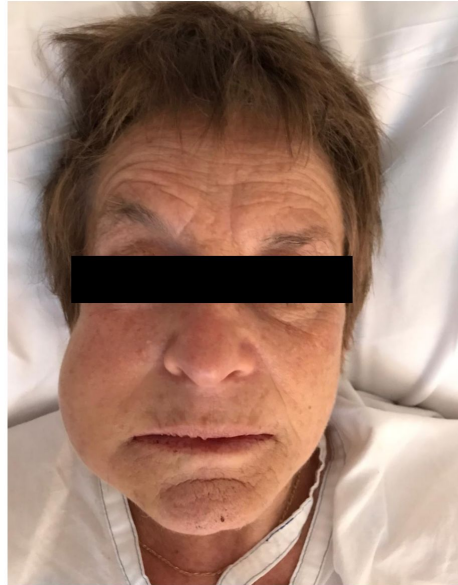- Most common complication
- Occurs when the blood clot undergoes fibrinolysis and the bony walls of the sockets become exposed
- Incidence: 3-5%
- Risk factors: smoking, OCP, poor oral hygiene
- Severe pain 48 hours after dental extraction
- Treatment
 - Conservative: resolves 2-3 weeks
 - Alvogyl
 - Curettage and re-establish blood clot



Postoperative complications

Infection

- D3-5 postoperative
- Signs: swelling, redness, pain, heat, purulent discharge
- Ensure that no foreign bodies, tooth/root fragments, bony sequestrum present
- Assess for trismus, dysphagia, odynophagia, mouth opening, upper airway obstruction, signs of systemic infection
- Treatment
 - Irrigation and drainage
 - Antibiotics
 - Review

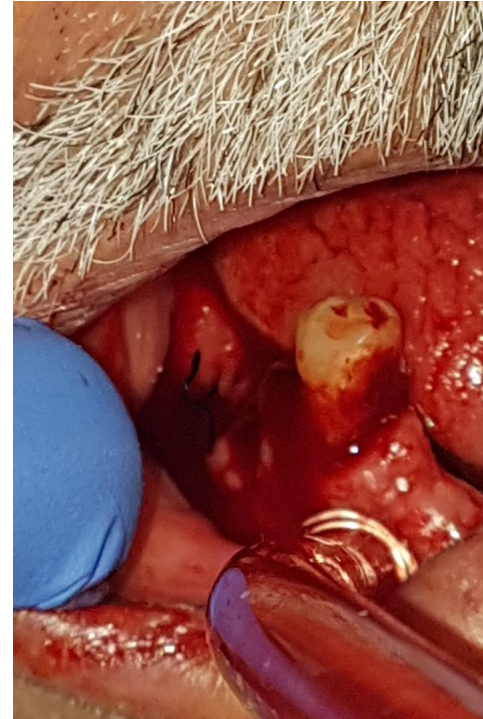

*Further information to be presented in “Infection” lecture

Postoperative complications

Postoperative haemorrhage

- Presents within the first few days postop
- Can result in significant blood loss
- Due to delayed primary bleeding or secondary bleeding
- Assessment: Primary survey
- Treatment
 - Once haemodynamically stable, consider using local methods to control bleeding
 - Review medical history
 - Once haemostasis achieved, requires close follow-up



Postoperative complications

Nerve injury

Injury to IAN, mental nerve and/or lingual nerve

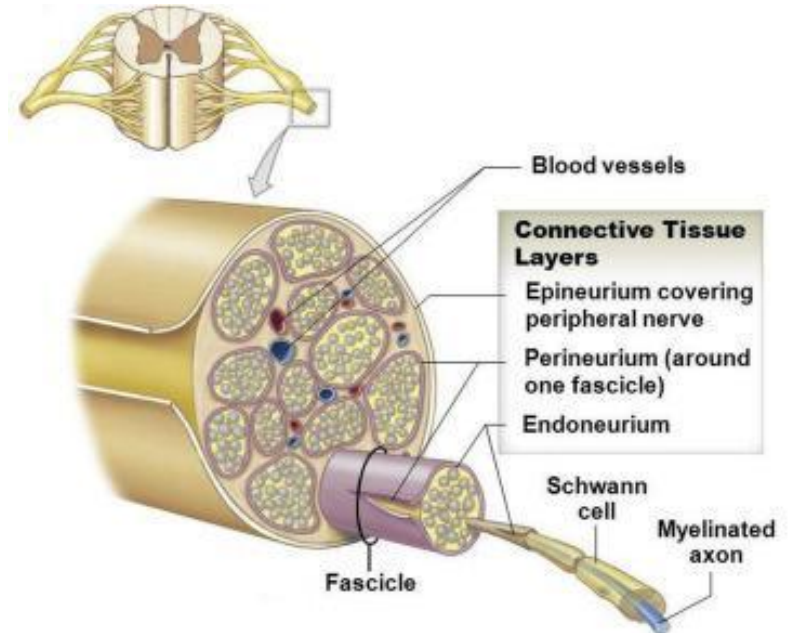
Injuries: temporary paraesthesia, permanent paraesthesia or dysaesthesia

Types of nerve injury

Seddon's classification

- Neuropraxia
- Axonotmesis
- Neurotmesis

Nerve healing rate: 1 mm/day



Postoperative complications

Assess lingual and IAN function

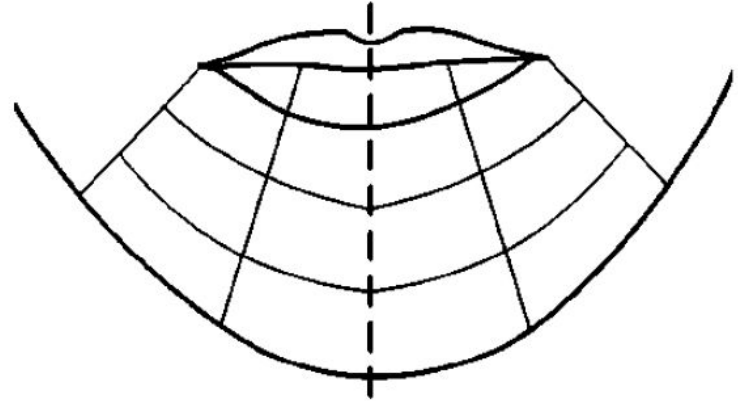
Often raised by the patient without prompting
as it has a notable effect on QoL

Assessment:

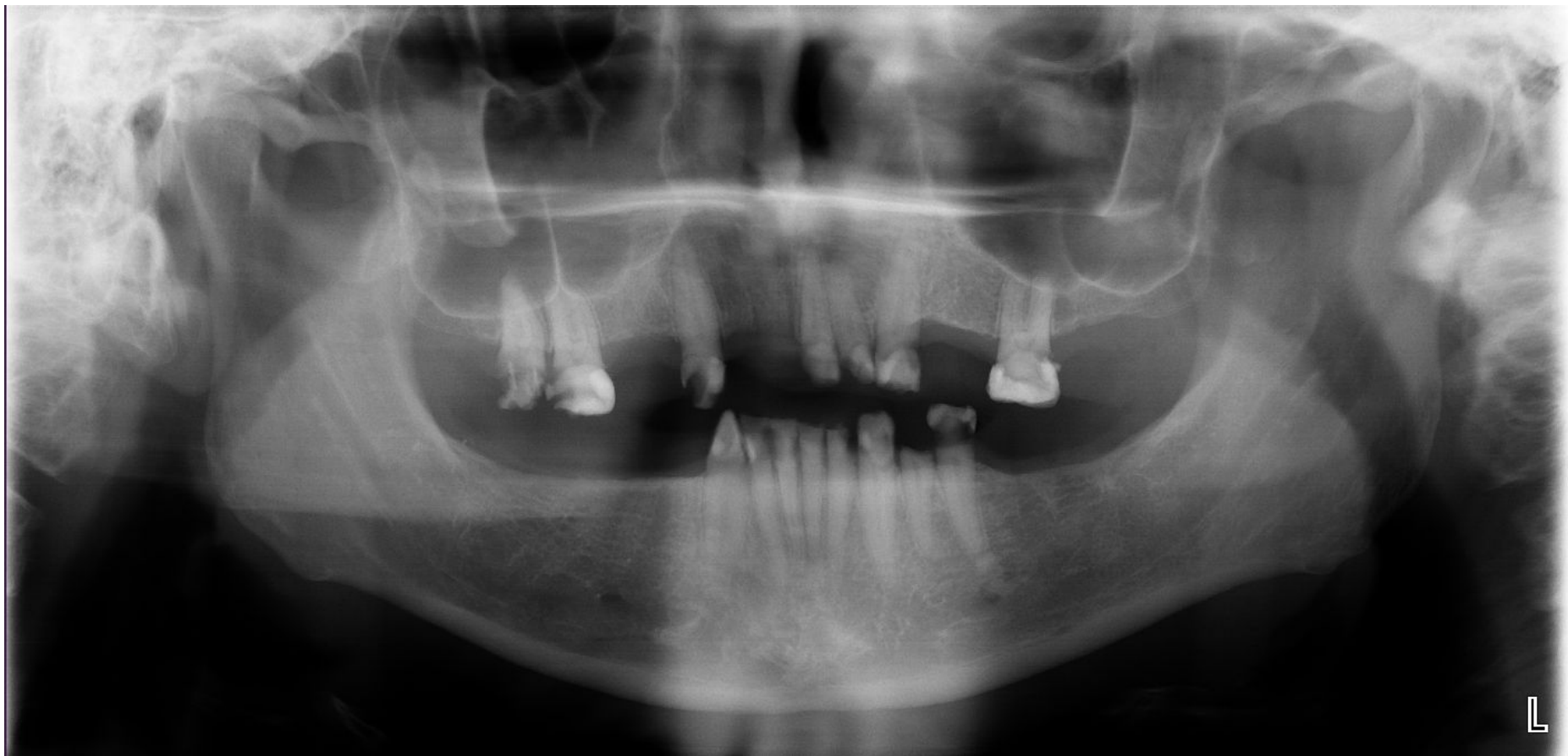- Objective and subjective
- Nerve mapping
- 2-point discrimination
- Temperature assessment (cold)

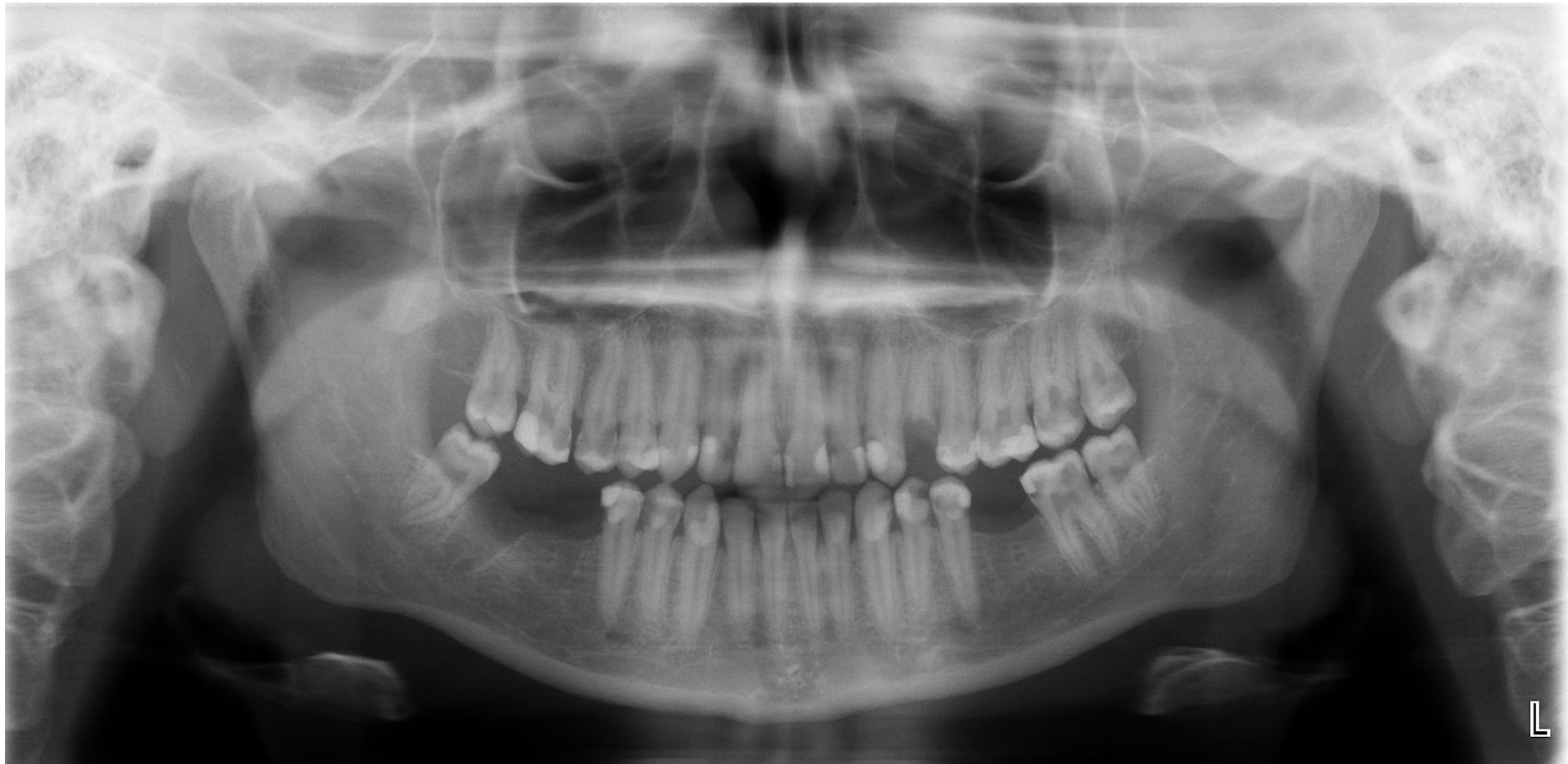Collect baseline measurements

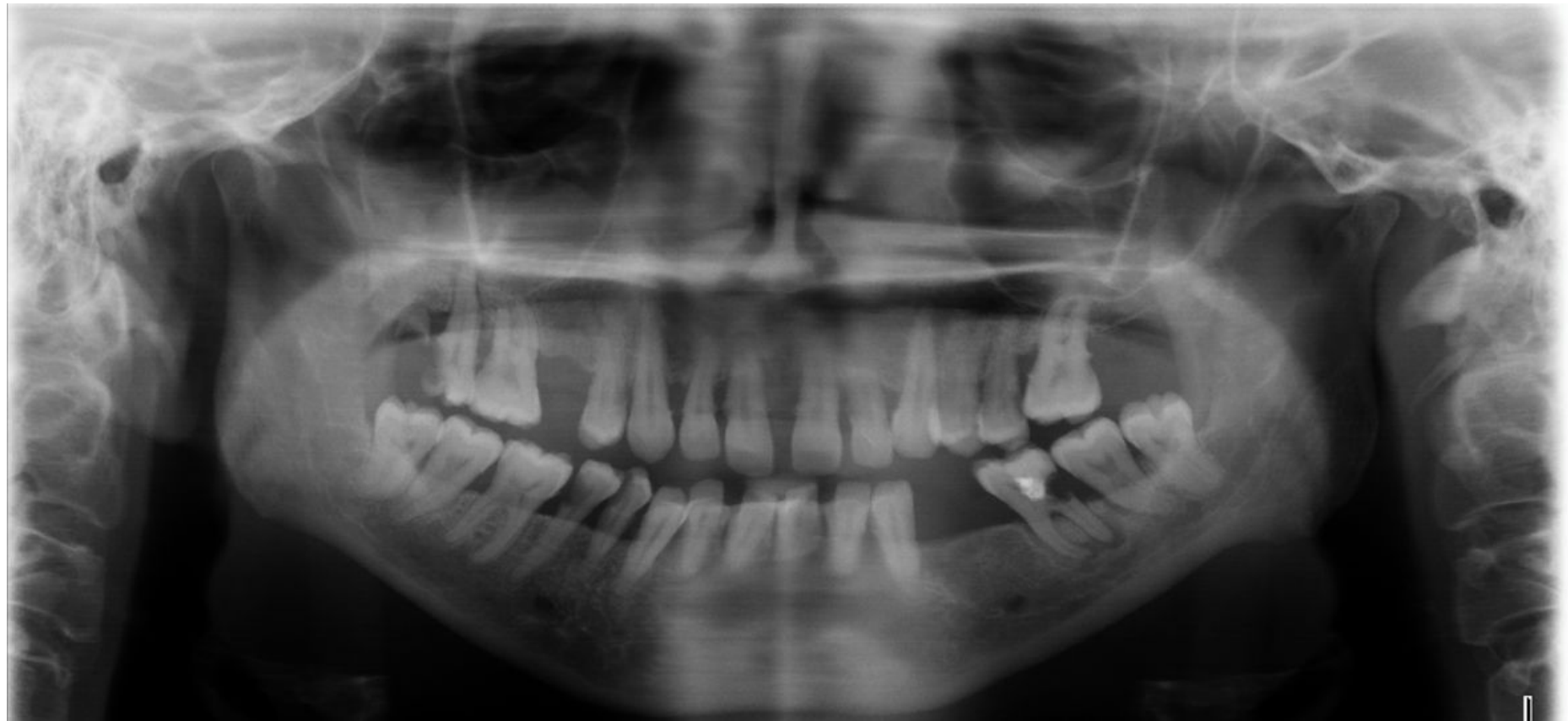Refer to OMFS early for assessment

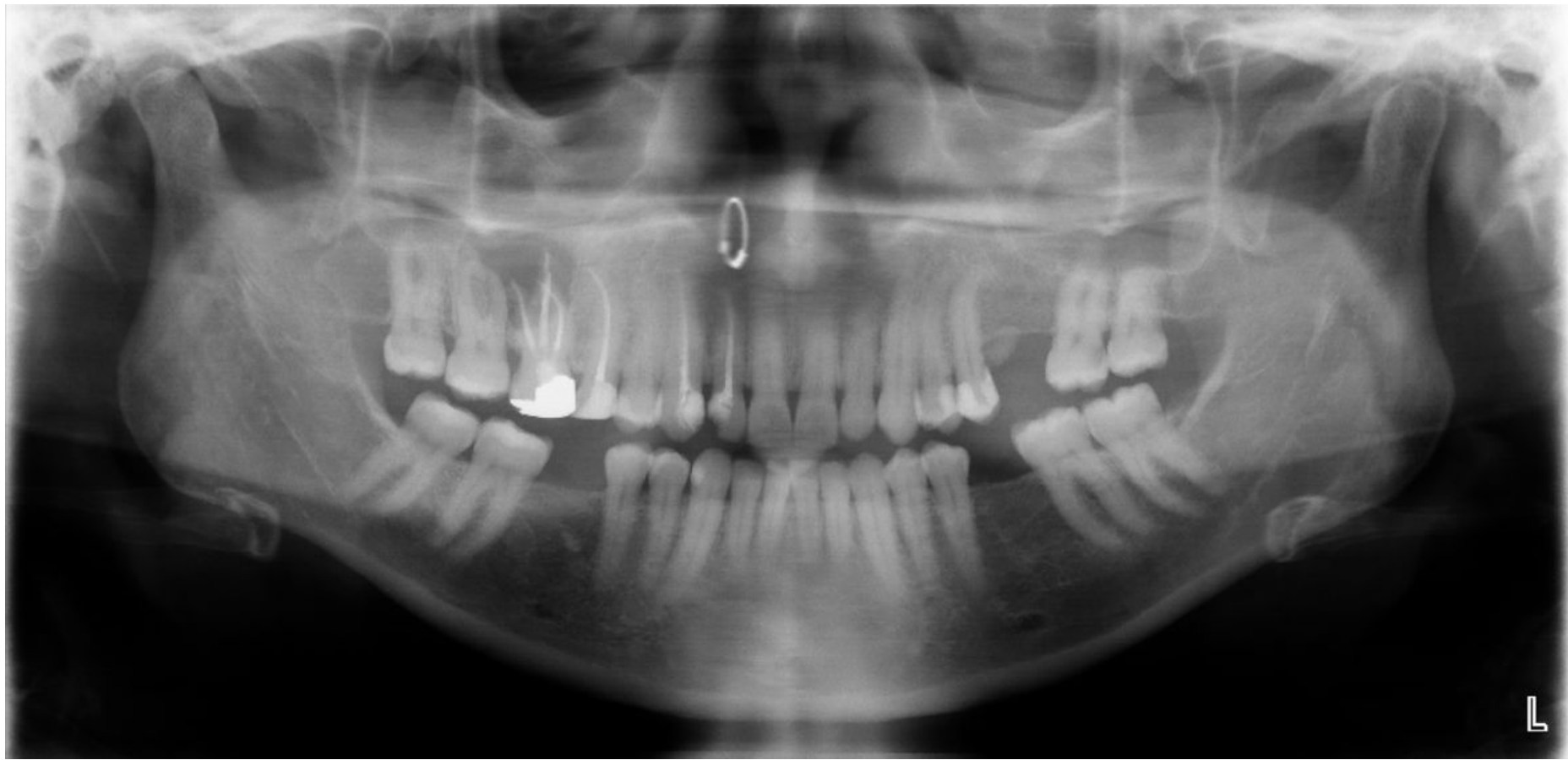

Treatment Planning









References

HUTCHESON, A., CHENG, A., KUNCHAR, R., STEIN, B., SAMBROOK, P. & GOSS, A. 2014. A C-terminal crosslinking telopeptide test-based protocol for patients on oral bisphosphonates requiring extraction: a prospective single-center controlled study. *J Oral Maxillofac Surg*, 72, 1456-62.

KUNCHUR, R., NEED, A., HUGHES, T. & GOSS, A. 2009. Clinical investigation of C-terminal cross-linking telopeptide test in prevention and management of bisphosphonate-associated osteonecrosis of the jaws. *J Oral Maxillofac Surg*, 67, 1167-73.

RUGGIERO, S. L., DODSON, T. B., FANTASIA, J., GOODDAY, R., AGHALOO, T., MEHROTRA, B. & O'RYAN, F. 2014. American Association of Oral and Maxillofacial Surgeons position paper on medication-related osteonecrosis of the jaw--2014 update. *J Oral Maxillofac Surg*, 72, 1938-56.

MARX, R. E., CILLO, J. E., JR. & ULLOA, J. J. 2007. Oral bisphosphonate-induced osteonecrosis: risk factors, prediction of risk using serum CTX testing, prevention, and treatment. *J Oral Maxillofac Surg*, 65, 2397-410.

NGUYEN, E., GRUBOR, D. & CHANDU, A. 2014. Risk factors for permanent injury of inferior alveolar and lingual nerves during third molar surgery. *J Oral Maxillofac Surg*, 72, 2394-401.

SAMBROOK, P. J. & GOSS, A. N. 2018. Contemporary exodontia. *Aust Dent J*, 63 Suppl 1, S11-s18.